

Sneddon's syndrome as a disorder of small arteries with endothelial cells proliferation: ultrastructural and neuroimaging study

Eliza Lewandowska¹, Teresa Wierzba-Bobrowicz¹, Teresa Wagner⁵, Romana Bogusławska², Anna Rudnicka³, Anna Leszczyńska⁴, Elżbieta Pasennik¹, Waldemar Lechowicz¹, Tomasz Stępień¹, Włodzimierz Kuran³

¹Department of Neuropathology, ²Department of Neuroradiology, ³1st Department of Neurology, ⁴3rd Department of Psychiatry, Institute of Psychiatry and Neurology, Warsaw, ⁵Department of Pathomorphology, Institute of Rheumatology, Warsaw, Poland

Folia Neuropathol 2005; 43 (4): 345-354

Abstract

We report a 18-year-old female patient with livedo reticularis and neurological disturbances. CT scan showed two big ischemic focuses in the pons, moreover MRI revealed small disseminated ischemic focuses in the pons and deep structures of both brain hemispheres. MRA demonstrated no changes in the big extracranial and intracranial arteries. Since the clinical data and neuroimaging results suggested Sneddon's syndrome, the skin and skeletal muscle biopsy was taken to examine.

The immunohistochemical and ultrastructural investigations of the skin biopsy revealed a significant reduction of the lumen of the capillaries and small to medium-sized arteries. Cells surrounding the vascular lumen, frequently with multilayer arrangement and their nuclei placed perpendicularly to the lumen, were CD31, CD34, and sporadically SMA positive. At the ultrastructural level, these proliferating cells showed typical features of endothelial cells: abundant intermediate filaments and Weibel-Palade bodies. Between the endothelial cells some junctions were detached as well in the capillaries as in the small arteries. The smooth muscle cells of the small arteries were electron denser than usual and their cytoplasmic protrusions penetrated to the endothelial cells. The ultrastructural picture of some vessels with a considerably narrow lumen was typical of vessels newly formed during angiogenesis. Neuroimaging including TC, MRI, MRA besides histological, immunohistochemical and ultrastructural evaluation may be useful for diagnosis of Sneddon's syndrome.

Key words: Sneddon's syndrome, skin and muscle biopsy, blood vessel, angiogenesis, endothelial cells, ultrastructure.

Introduction

Sneddon's syndrome is characterized by association of livedo reticularis (typical skin lesions) and cerebrovascular diseases: stroke or transient ischemic attack [1,7,23]. This disease is a rare progressive disorder of unknown aetiology, affecting

small and medium-sized arteries of the skin and the brain [23,32]. The pathological change is noninflammatory occlusive arteropathy [21,25]. The disease usually starts with vascular pathology in the epidermis but neurological defects become evident later [31]. For this reason, examination of skin biopsy

Communicating author:

dr Eliza Lewandowska, Department of Neuropathology, Institute of Psychiatry and Neurology, Sobieskiego 9, 02-957 Warsaw, Poland, e-mail: lewandow@ipin.edu.pl

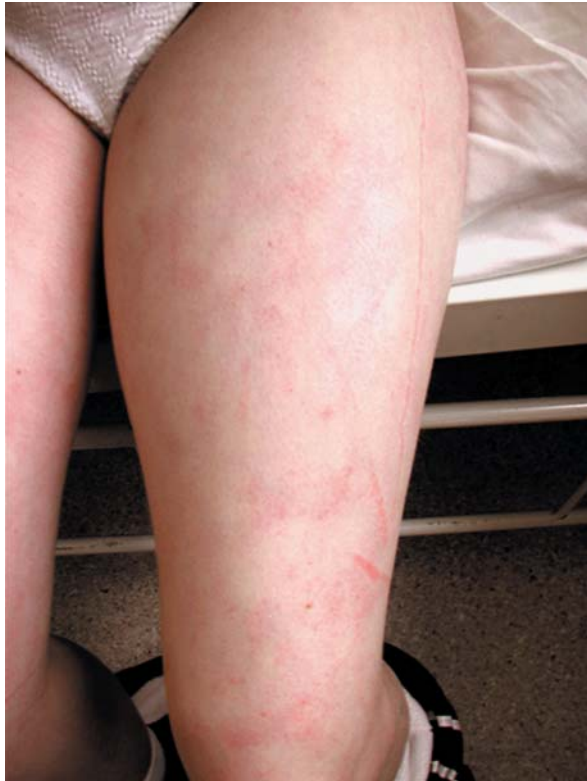

Fig. 1. Skin sign of livedo reticularis and a small irregular sign of livedo racemosa (19-year-old female patient)

has a particular importance for the early diagnosis [31]. Sneddon's syndrome mainly affects women before or during middle age [10]. The clinical differentiation of Sneddon's syndrome from other phenomenologically similar disorders may be difficult [12,16,19,26] and requires supplementary examinations.

We present histological, immunohistochemical, ultrastructural, and neuroimaging methods used commonly for an early diagnosis of Sneddon's syndrome. Special attention was focused on ultrastructural examinations of the skin and muscles, since, to our knowledge, there are only a few data concerning ultrastructural examination of the blood vessels in diagnosis of Sneddon's syndrome to date [18,24].

Case report

A 18-year-old woman had been well until 2 years earlier when the non-specific prodromal symptoms (headache, vertigo) and *livedo reticularis* developed. Dermatological examination revealed *livedo reticularis* on both lower legs and the trunk (Fig. 1). These skin

lesions were exacerbated by cold. Additionally, a diagnosis of labile hypertension was made. Two years later she was first seen at our ward. On the neurological examination, she was well oriented and cognition was intact. There was mild dysarthria. The right pupil was 8 mm, and the left 6 mm; both constricted normally. A prominent peripheral left facial weakness was evident. The remaining cranial-nerve functions were intact. The patient barely lifted her left arm from a bed; the distal muscles of the left upper extremity were graded 3-4/5 in motor power; she lifted her left leg 10 cm off the bed against minimal resistance; the distal leg muscles were graded 4/5; the right extremities were graded 5/5. The deep tendon reflexes were ++ in the right extremities and +++ in the left; left Babinski, Oppenheim and Chaddock signs were present. The cerebrospinal fluid (CSF) was normal and its protein electrophoresis did not show any presence of discrete bands in the immunoglobulin G (IgG) region.

Complete blood count and differential count (CBC & DC), prothrombin time, activated partial thromboplastin time, electrolytes (Na, K, Cl) were all within a normal limit.

Tests for lupus anticoagulant, antinuclear antibody (ANA), and antiphospholipid antibodies, cryoglobulin, human immune deficiency virus (HIV), Coxsackie and ECHO viruses, tuberculosis (PCR) were all negative.

Material and methods

The samples of skin and skeletal muscles were fixed in buffered formalin, and embedded in paraffin. Sections were stained with hematoxylin and were immunostained with the following antibodies: smooth-muscle actin (SMA) DAKO 1:75, CD31 DAKO 1:20, and CD34 Novocastra 1:25.

For the ultrastructural studies, the small samples were fixed by immersion in 2.5% glutaraldehyde with post-fixation in osmium tetroxide, and routinely processed into epoxy resin. The arteries were identified on semithin sections stained with toluidyne blue, and ultrathin sections were cut from the selected area. The ultrathin sections were contrasted with uranyl acetate and lead citrate, and examined with a transmission electron microscope (Opton DPS 109).

Results

The light microscopy revealed a significant reduction of a vascular lumen in the capillaries, small

and medium arteries of the skin, and in muscle samples (Fig. 2, 3). Proliferation of endothelial cells, frequently with multilayer arrangement with their nuclei placed perpendicularly to the vascular lumen and/or basement membrane, was visible (Fig. 2). The basement membrane was often thickened (Fig. 3). The proliferating cells were positive with antibody CD34, CD31 and sporadically with SMA (Fig. 2c).

In the skin biopsy, the electron microscopy showed that the capillaries, like small and medium-sized arteries had a different range of lumen reduction and often resembled a narrow crevice (Fig. 4-7). In the cytoplasm of the cells surrounding the lumen of the vessels the abundant filaments (about 10 nm in diameter – a diameter of the indirect filaments) were present. They were usually organized in bundles frequently filling a substantial part of the cytoplasm (Fig. 8, 9). Their nuclei were often folded or invaginated (Fig. 7, 8). In these cells, Weibel-Palade bodies and numerous pinocytotic vesicles under plasmalemma, were seen (Fig. 8, 9). In some of the capillaries and the small arteries junctions between the endothelial cells were partially detached, sometimes forming prominent extensions (Fig. 10, 11). Outside the endothelia, the smooth muscle cells characterized by attachment plaques, were located (Fig. 12-14). Some of them were electron denser than normal ones and their cytoplasmic protrusions penetrated to the endothelial cells (Fig. 14). The capillaries with ultrastructural picture typical of proliferating vessels were also observed (Fig. 11). Their endothelial cells produced numerous cytoplasmic protrusions, both at the lumen and abluminal surface (Fig. 12, 14).

Vessels with the different range of the lumen reduction were also observed in the skeletal muscle. Contrary to the skin, in the muscle biopsy, the cells surrounding the vessels lumen were characterized by a large number of pinocytotic vesicles as well as under plasmalemma and in the all cytoplasm, but proliferation of filaments was not to seen (Fig. 15).

CT scans showed only two big ischemic focuses in the pons (Fig. 16a,b). Additionally, MRI picture revealed some small disseminated ischemic focuses in the pons (Fig. 17) and in the deep structure of both brain hemispheres, the biggest one was placed in the right thalamus (Fig. 18). MRA showed no changes in big extracranial and intracranial arteries (Fig. 19a,b).

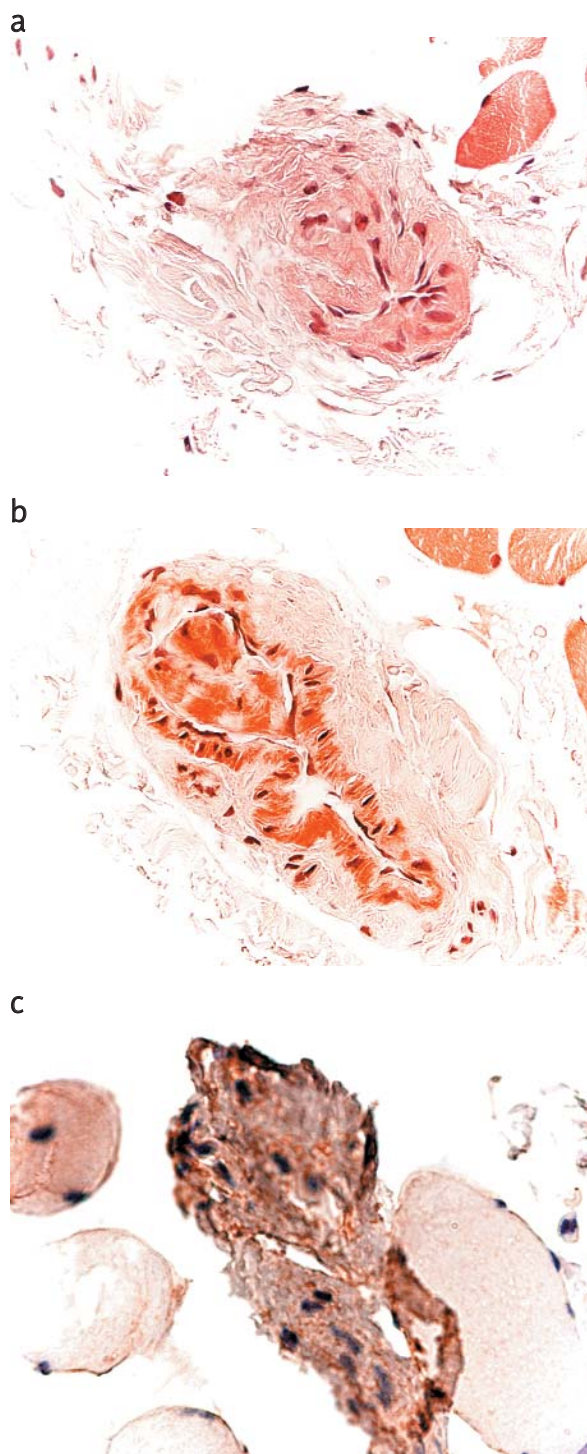


Fig. 2. Skeletal muscles samples. (a) A vessel occluded by proliferating endothelial cells, x630. (b) A vessel with narrow lumen and numerous endothelial cells with large clear cytoplasm. H&E, x400. (c) Positive reaction of proliferating cells with antibody CD31, x630

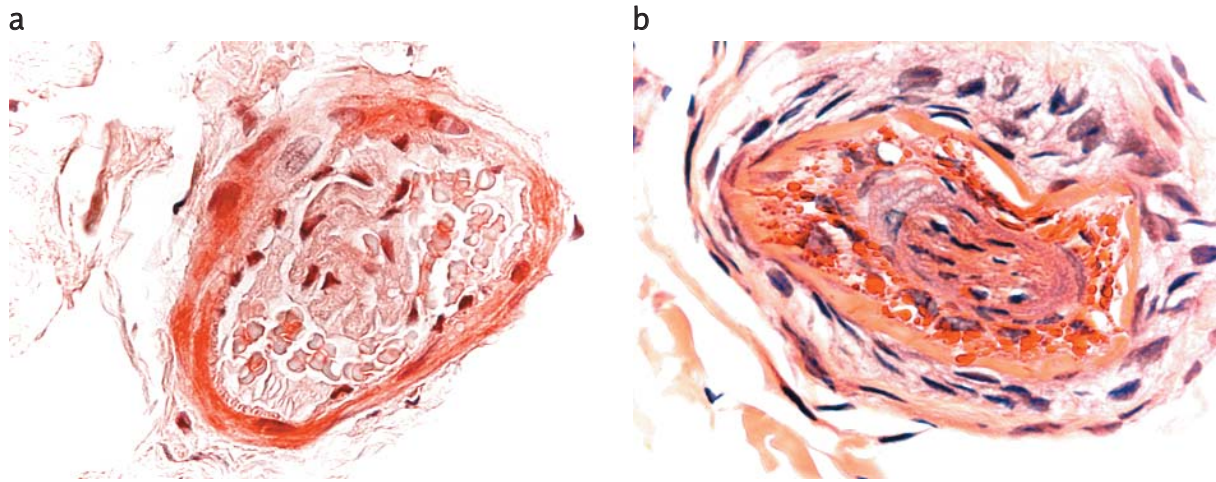


Fig. 3. Skin samples. (a) Endothelial cells with varying degrees of atypia inside vascular lumen. The basement membrane is thickened. x630 (b) Numerous infiltrating erythrocytes between endothelial cells and basement membrane. Vessel lumen is invisible. H&E, x630

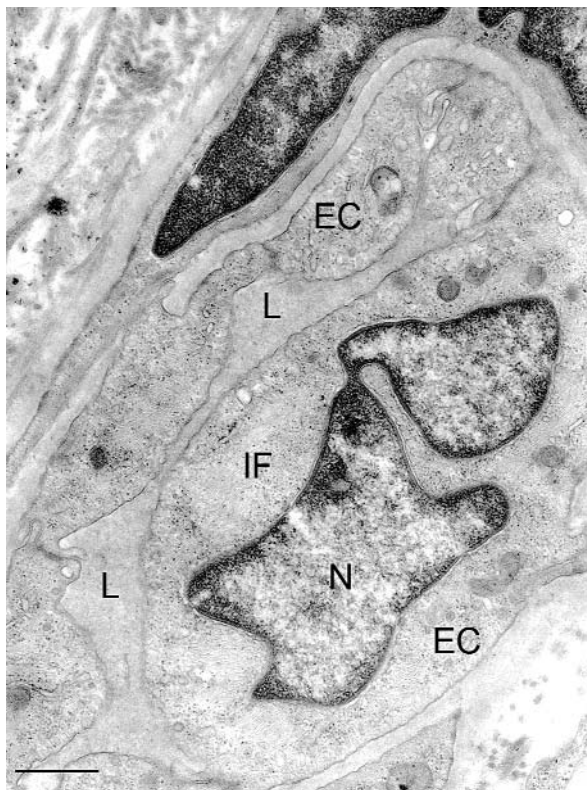


Fig. 4. A small artery in the skin biopsy with markedly reduced of lumen (L). The lobular nucleus (N), numerous intermediate filaments (IF) in the endothelial cell (EC). Bar represents 0.5 μm

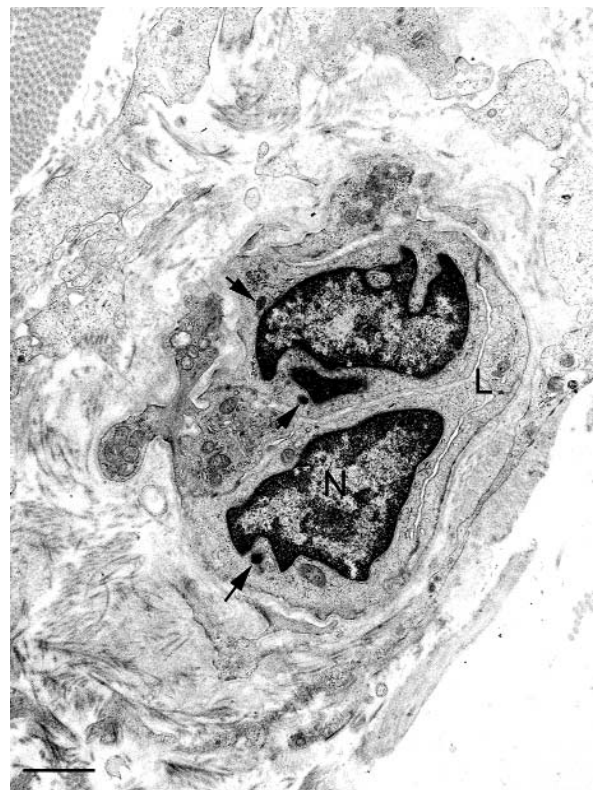


Fig. 5. A small artery in the skin biopsy with creviced lumen (L). The nuclei (N) irregular shaped, and Weibel-Palade bodies (arrows) in endothelial cells. Bar represents 1 μm

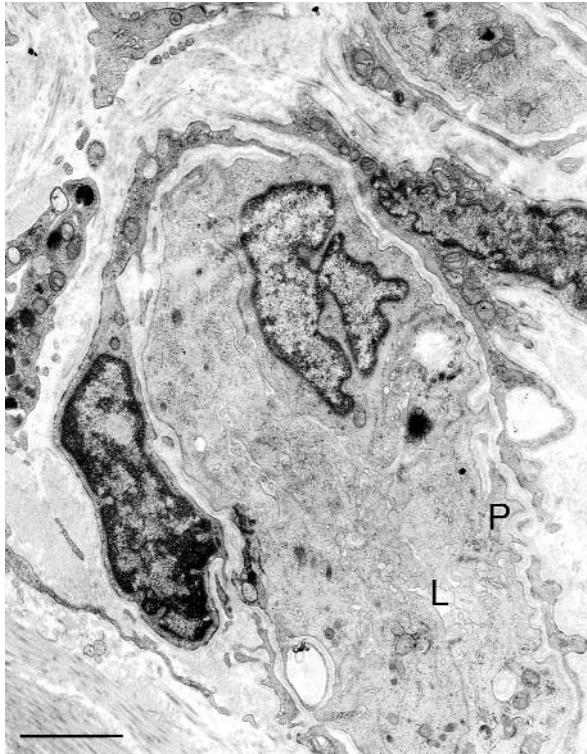


Fig. 6. The blood vessel with rudimentary lumen (L). Abluminal cytoplasmic protrusions (P). Bar represents 1 μ m

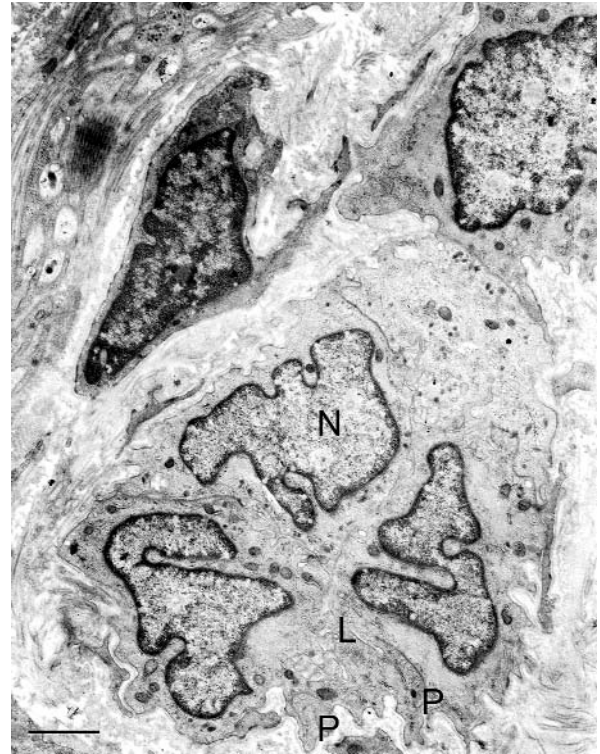

Fig. 7. The blood vessels with rudimentary lumen (L). Lobular nuclei (N) in endothelial cells and abluminal cytoplasmic protrusions (P). Bar represents 1 μ m

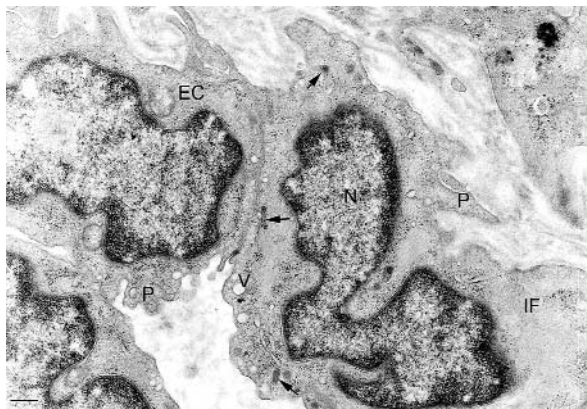


Fig. 8. The endothelial cells (EC) with numerous intermediate filaments (IF), vesicles (V), Weibel-Palade bodies (arrows) and lobular nuclei (N). On the luminal and abluminal surface protrusions (P). Bar represents 1 μ m

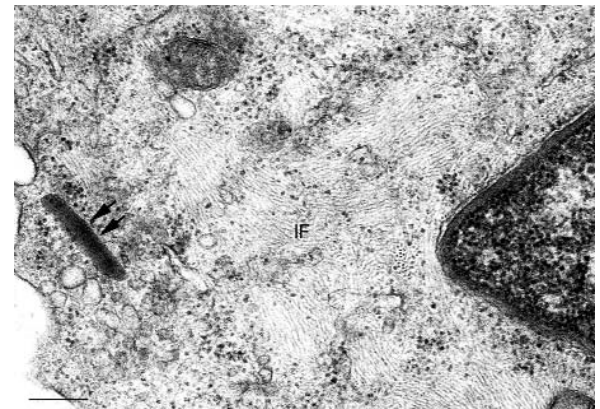


Fig. 9. High magnification of cytoplasm of the endothelial cell with numerous intermediate filaments (IF) and Weibel-Palade body (arrows). Bar represents 0.5 μ m

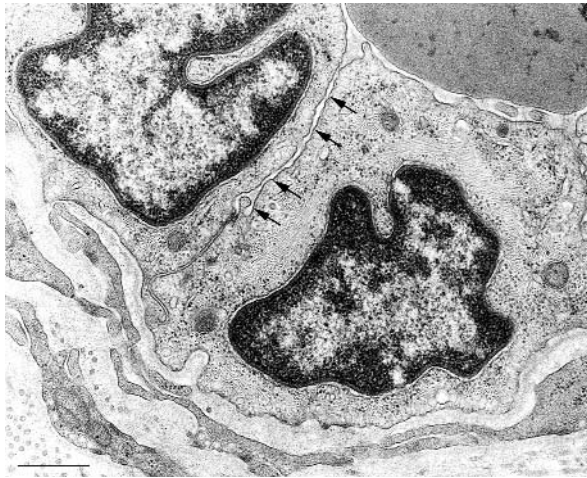

Fig. 10. The junction between endothelial cells with broadened space of considerable length (arrows). Bar represents 1 μm

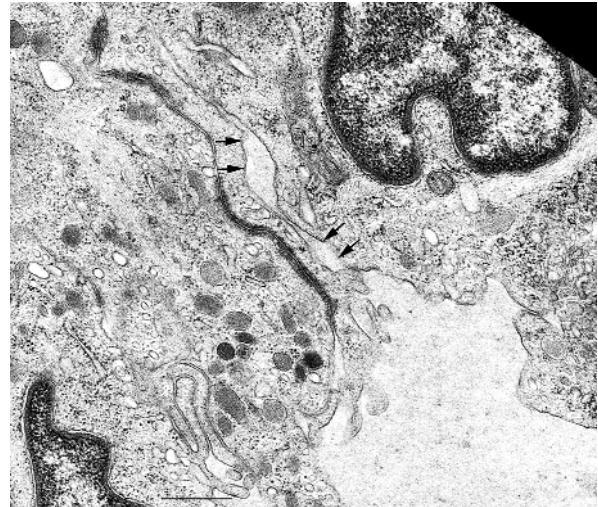

Fig. 11. The big extension between two endothelial cells (arrows). Bar represents 1 μm

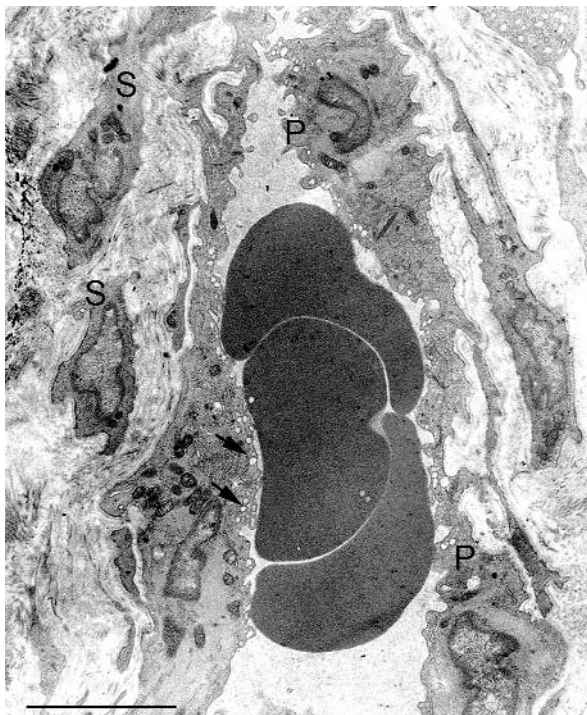


Fig. 12. The endothelial cells of the artery with cytoplasmic protrusions (P) and numerous vesicles (arrows) under the lumen surface. Outside endothelial cells, smooth muscle cells (S) are visible. Bar represents 5 μm

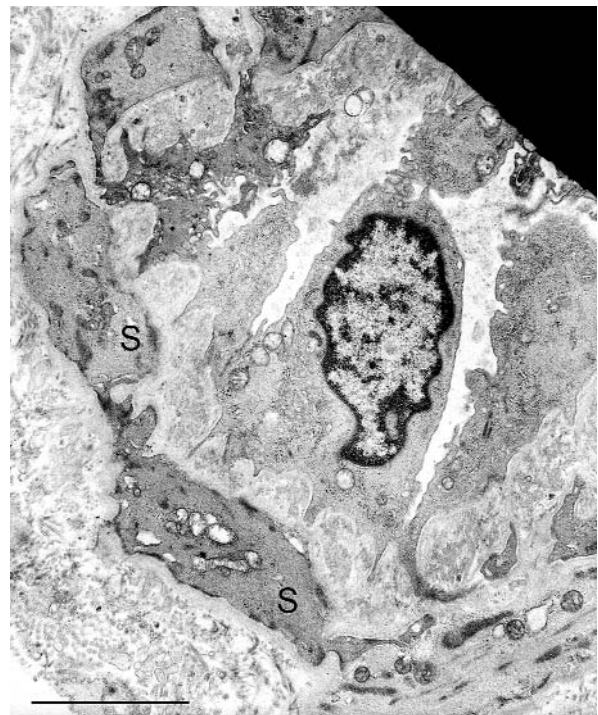


Fig. 13. The smooth muscle cells (S) in the wall of the artery. Bar represents 5 μm

Discussion

The relationship between livedo reticularis and cerebrovascular lesions was first reported by Sneddon in 1965 [25] as a clinical entity. The clinical findings of our patient, including the presence of livedo reticularis and particular neurological symptoms, suggested Sneddon's syndrome. To confirm Sneddon's syndrome diagnosis neuroradiological, immunohistochemical and ultrastructural investigations were performed.

MRI picture usually shows lacunar infarct and leukoaraoidosis; bilateral patchy of diffuse hyperintensive areas of signal alterations in the white matter, observed particularly on T2-weighted images, suggesting chronic ischemia and cortical atrophy. Progression of MRI changes indicates the correlation with a worsening clinical condition in the follow up [6,28]. Our CT scan and MRI demonstrated abnormalities that agree with earlier observations of other authors [4,6]. CT has shown ischemic focuses in

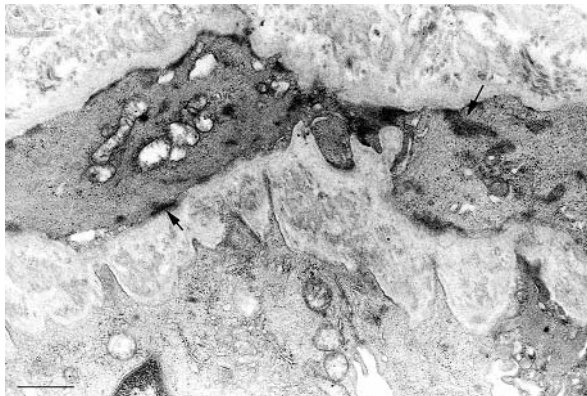


Fig. 14. High magnification of the smooth muscle cells with attachment plaques (arrows). Bar represents 2 μ m

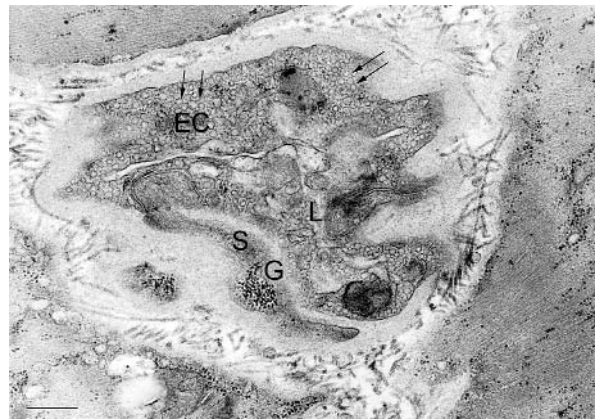

Fig. 15. A small artery in the skeletal muscles biopsy with narrow lumen (L). The cytoplasm of endothelial cells (EC) showing abundant vesicles (arrows). In the smooth muscle cell (S) of blood vessel the agglomeration of glycogen (G). Bar represent 1 μ m

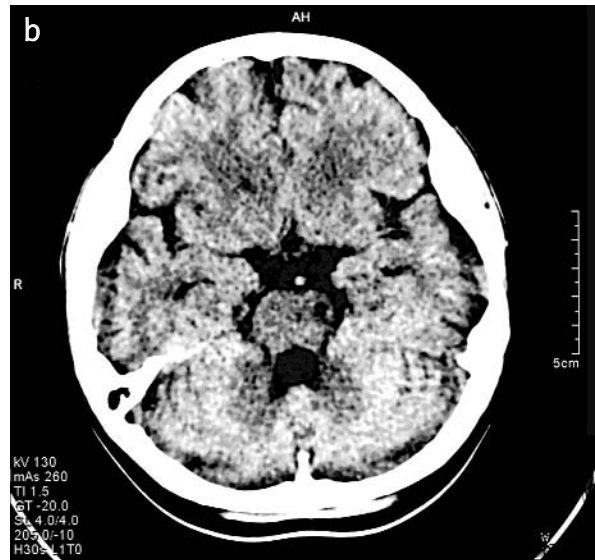
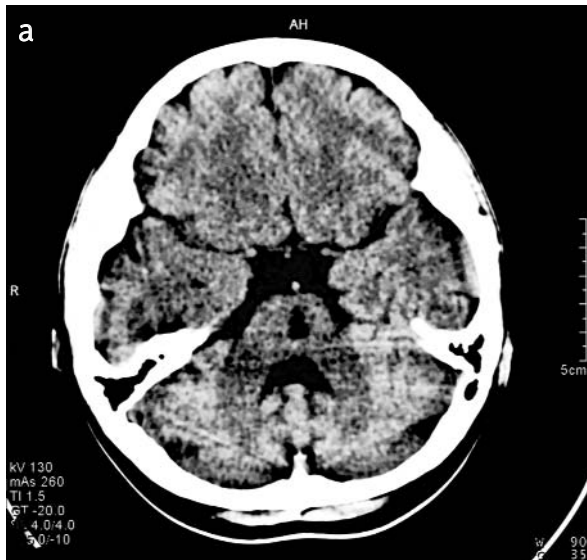


Fig. 16a, b. CT scan of the brain showing two hypodense focuses in: a) central part of the pons (biggest) and b) left cerebral peduncle (smaller)

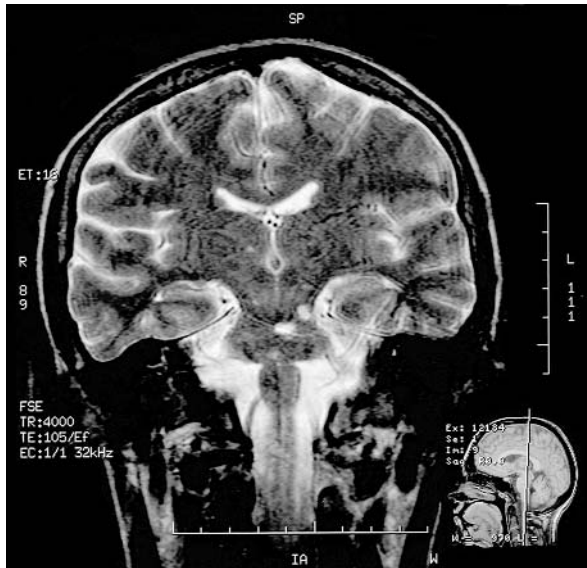

Fig. 17. MRI scan confirmed the presence of the ischemic foci previously seen in the CT scan

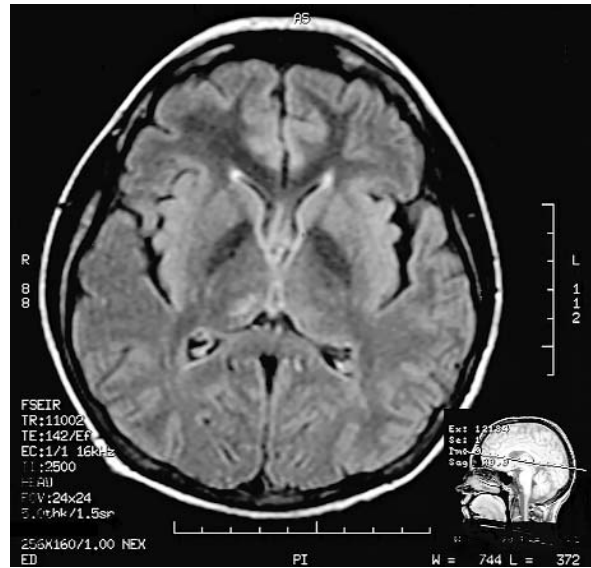


Fig. 18. FLAIR showing the third ischemic focus in the right thalamus

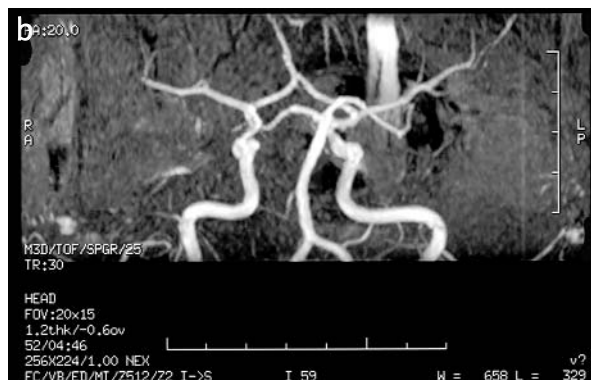
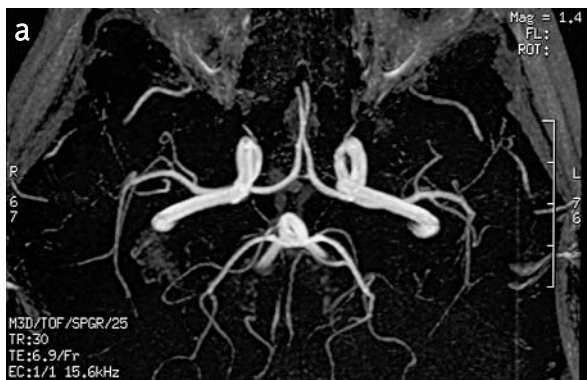
Fig. 19a, b. MRA showing normal Willson circle arteries and their main branches

the pons and MRI picture confirmed the CT findings and revealed the additional small disseminated ischemic foci in the deep structures of both brain hemispheres. Severity of the disease seems to be correlated with MR imaging aspects [28]. In our patient, MRA of the big extracranial and intracranial arteries appeared normal, which does not rule out that the pathology is still concerned around the small and medium-sized arteries.

Our data are in agreement with Tourbach et al. [28] that neuroimaging like CT, MR and MRA contribute to better understanding of the pathophysiology, and natural course of cerebral lesions in Sneddon's syndrome.

Our histological and ultrastructural examination of the skin and muscle biopsy revealed a significant

reduction of vascular lumen in the capillaries, and in the small and medium-sized arteries. Their basement membrane was often thickened. The cells surrounding the blood lumen were CD31 positive and contained Weibel-Palade bodies. It is commonly accepted that, besides the Weibel-Palade bodies, the immunoreactivity for factor VIII and CD31 are of the most specific to identify the endothelial cells [2,11,14]. On this basis, we believe that the proliferating cells surrounding the vascular lumen displayed the phenotype characteristic of endothelial cells. The most of the endothelial cells showed abundant intermediate filaments, frequently filling a substantial part of the cytoplasm and numerous pinocytotic vesicles. Such a fibrillary appearance of the cytoplasm is probably an

exaggerated intermediate filaments content in the cells [13]. A large number of intermediate filaments was observed in aging human lens epithelial cells and in many other degenerative, and aging cells [8,20]. The identity of the cells engaged in proliferation remained controversial, which has been already noted by Seep et al. [24]. Generally, our findings are in contrast to most observations of other authors, who claim that the lumen of vessels is occluded by subendothelial proliferating smooth muscle cells or myofibroblastic cells and noninflammatory thrombotic occlusions [15,18,22,31,32]. It was also observed that in the skin small to medium-sized arteries of the dermis-subcutis boundary are affected in a stage-specific sequence from stage I to stage IV, and that the cells involved in subendothelial proliferation displayed the phenotype characteristic of smooth muscle cells and were vimentin and actin positive but desmin negative [24]. However, in our immunohistochemical and ultrastructural investigations neither proliferation of the medial smooth muscle cells nor their presence in the lumen of the vessels was observed. However, the presence of endothelial cells, characterized by Weibel-Palade bodies among the smooth muscle cells in the occluded vessel lumen, was noted [24]. An endothelial origin of proliferating cells, which were factor VIII positive, was postulated earlier [9].

Between the endothelial cells with numerous intermediate filaments the junctions were often detached to a different degree. In our opinion, this picture may be comparable with the initial stage of changes described by Zelger et al. [32]. However, it is worth remembering that, in some cases, the mature vessels must be first destabilized to allow angiogenesis [29].

Our ultrastructural pictures indicate the formation of new vessels. Angiogenesis is a formation of new capillaries from the pre-existing vessels by migration and proliferation of the endothelial cells. It plays a key role in normal and pathological conditions, including diseases [5,27,30]. The ultrastructural picture of the endothelial cells during angiogenesis is comparable to endothelial activation [17]). The endothelial activation is characterized by the presence of luminal and abluminal protrusions, an increase of cytoplasmic organelles and basement membrane degradation [17].

The skin has a rich blood supply, but when stenoses or even occlusions occur in several neighbouring arterioles, tissue hypoxia develops [31]

and this, in our opinion, can lead to the proliferation of vessels.

Additionally, cerebral angiography is abnormal in approximately 75% of Sneddon's syndrome cases. The common findings are an obliterating noninflammatory arteriopathy with stenosis or occlusion of the intracranial vessels and the so called pseudo-angiomas presented by vessels malformations like transdural anastomoses, a wide network of fine collateral branches or granulomatous leptomeningeal infiltration. The name pseudoangiomas comes from the term angiomas, but in this case there is no evidence for neoplastic vascular proliferation. We support the view that in the course of Sneddon's syndrome the process of leptomeningeal vessels proliferation (pseudoangiomas) may be due to the repeated episodes of ischemia [3].

Most cerebrovascular events in Sneddon's syndrome are ischemic lesions in the brain, but there are some case reports about intracranial haemorrhage. The suspected mechanism seems to be rupture of an abnormal vessel. [3].

To sum up, we believe that the picture of the vessels in our skin and muscle samples results from the area selected for biopsy. The histological changes in the arterioles of the skin within an area of racemose livedo are irregularly distributed, so a place selected for biopsy would be therefore of decisive importance [31].

Our findings, on the basis of immunohistochemical and electron microscopy examination, suggest that the occlusions of the capillaries and the small arteries are composed of the endothelial cells. Clinical data and neuroimaging pictures support the Sneddon's syndrome diagnosis. Further investigations in this field are necessary for a better understanding of the pathogenesis and the course of the illness.

References

1. Abouzahir A, Bourazza A, Rafik R, Karouach K, Boutaleb N, Ouhabi H, Mosseddaq R, Ohayon V, Archane MI. Sneddon's syndrome: 4 cases and review of the literature. *Rev Neurol (Paris)* 2003; 12: 1156-1162.
2. Alles JU, Bosslet K. Immunocytochemistry of angiosarcomas: a study of 19 cases with special emphasis on the applicability of endothelial cell specific markers of routinely prepared tissues. *Am J Surg Pathol* 1998; 89: 463-471.
3. Aquino Gondim F de A, Leacock RO, Subramanian TA, Cruz-Flores S. Intracerebral hemorrhage associated with Sneddon's syndrome: is ischemia-related angiogenesis the cause? Case report and review of the literature. *Neuroradiology* 2003; 45: 368-372.

4. Blom RJ. Sneddon's syndrome: CT, arteriography and MR imaging. *J Comput Assist Tomogr* 1989; 13: 119-122.
5. Distler O, Neidhart M, Gay RE, Gay S. The molecular control of angiogenesis. *Inter Rev Immunol* 2002; 21: 33-49.
6. Fetoni V, Grisoli M, Sallmaggi A, Carriero R, Girotti F. Clinical and neuroradiological aspects of Sneddon's syndrome and primary antiphospholipid antibody syndrome. A follow-up study. *Neurol Sci* 2000;21: 157-164.
7. Franc?s C, Papo T, Wechsler B, Laporte JL, Bioussé V, Piette JC. Sneddon syndrome with or without antiphospholipid antibodies. A comparative study in 46 patients. *Medicine (Baltimore)*1999; 4: 209-219.
8. Ghadially FN. Ultrastructural pathology of the cell and matrix. 4th ed. London: Butterworths; 1997: 1-1414.
9. Grattan CEH, Burton JL, Boon AP. Sneddon's syndrome (livedo reticularis and cerebral thrombosis) with livedo vasculitis and anticardiolipin antibodies. *Br J Dermatol* 1989; 120: 441-447.
10. Gretchen E Tietjen, Al-Qasbi MM, Shukairy MS. Livedo reticularis and migraine: a marker for stroke risk? *Headache* 2002; 42: 352-355.
11. Leader M, Collins M, Patel J, Henry K. Staining for factor VIII related antigen and Ulex europaeus agglutinin I (UEA-1) in 230 tumours, an assessment of their specificity for angiosarcoma and Kaposi's sarcoma. *Histopathol* 1986; 10: 1153-1162.
12. Levine SR, Langer SL, Albers JW, Welch KMA. Sneddon's syndrome: An antiphospholipid antibody syndrome? *Neurology* 1988; 38: 798-800.
13. Khalil AK, Kubota T, Tawara A, Inomata H. Early changes in iris blood vessels in exfoliation syndrome. *Curr Eye Res* 1998; 1124-1134.
14. Mackay B, Ordonez NG, Huang WL. Ultrastructural and immunohistochemical observations on angiosarcomas. *Ultrastruc Pathol* 1989; 13: 97-110.
15. Marsch WC, Muckelmann R. Generalized racemose livedo with cerebrovascular lesions (Sneddon syndrome); an occlusive arteriopathy due to proliferation and migration of smooth muscle cells. *Br J Dermatol* 1985; 112: 703-708.
16. Martinez-Menendez B, Perez-Sempere A, Gonzalez-Rubio M, Villaverde-Amundarain FJ, Bermejo-Pareja F. Sneddon's syndrome with negative antiphospholipid antibodies (letter). *Stroke* 1990; 21: 1510-1511.
17. Masuda H, Kawamura K, Nanjo H, Sho E, Komatsu M, Sugiyama T, Sugita A, Asari Y, Kobayashi M, et al. Ultrastructure endothelial cells under flow alteration. *Mic Res Tech* 2003; 60: 2-12.
18. Al Meshari K Al, Eisa A Al, Akhtar. Sneddon's syndrome: A systemic arterio-occlusive disorder. *Am J Kid Dis* 1995; 26: 368-372.
19. Moral A, Vidal JM, Moreau I, D'Olhaberriague L, Montalban J. Sneddon's syndrome with antiphospholipid antibodies and arteriopathy (letter). *Stroke* 1991; 22: 1327-1328.
20. Perry MM, Tassin J, Courtois YA. Comparison of human lens epithelial cells in situ and in vitro in relation to aging: an ultrastructural study. *Exp Eye Res.* 1979; 28: 327-341.
21. Rebollo M, Val JF, Quintana F, Berciano J. Livedo reticularis and cerebrovascular lesions (Sneddon's syndrome): clinical, radiological and pathological features in eight cases. *Brain* 1983; 106: 965-979.
22. Roeckl H, Metz J. Symptom: Livedo. In: Braun-Falco O, Wolff HH, eds, *Fortschritte der prak. Dermatologie und Venerologie*. Vol 9. Berlin: Springer-Verlag 1979: 163-170.
23. Schellong SM, Weissenborn K, Niedermeyer J, Wollenhaupt J, Sosada M, Ehrenheim C, Lubac. Classification of Sneddon Syndrome. *Vasa* 1997; 26: 215-221.
24. Sepp N, Zelger B, Schuler G, Romani N, and Fritsch P. Sneddon's syndrome-An inflammatory disorder of small arteries followed by smooth muscle proliferation. *Am J Surg Pathol* 1995; 4: 448-453.
25. Sneddon IB. Cerebrovascular lesions and livedo reticularis. *Br J Dermatol* 1965; 77: 180-185.
26. Stockhammer G, Felber SR, Zelger B, Sepp N, Birbamer GG, Fritsch PO, Aichner FT. Sneddon's syndrome: diagnosis by skin biopsy and MRI in 17 patients. *Stroke* 1993; 24: 685-690.
27. Szpak GM, Lechowicz W, Lewandowska E, Bertrand E, Wierzba-Bobrowicz T, Dymecki J. Order zone neovascularization in cerebral ischemic infarct. *Folia Neuropathol* 1999; 4: 264-268.
28. Tourbah A, Piette JCH, Iba-Zizen MT, Lyon-Caen O, Godeau P, Franc?s C. The natural course of cerebral lesions in Sneddon syndrome. *Arch Neurol* 1997; 54: 53-60.
29. Ware JA, Simons M. Angiogenesis in ischemic heart disease. *Nat Med* 1997; 3:158-164.
30. Wierzba-Bobrowicz T, Lewandowska E. Morphological study of endothelial cells in the human fetus during early period of gestation. *Folia Neuropathol* 1995; 4: 241-245.
31. Wohlrab J, Fischer M, Wolter M and Marsch. Diagnostic impact and sensitivity of skin biopsies in Sneddon's syndrome. A report of 15 cases. *Br J Dermatol* 2001; 141: 285-288.
32. Zelger B, Sepp N, Schmid KW, Hinter H, Klein G, Fritsch PO. Life history of cutaneous vascular lesions in Sneddon's syndrome. *Hum Pathol* 1992; 23: 668-875