

Cerebral amyloid angiopathy manifested as a brain tumour. Clinical and neuropathological characteristics of two cases

Aleksandra Karbowniczek¹, Teresa Wierzba-Bobrowicz¹, Tadeusz Mendel², Paweł Nauman³

¹Department of Neuropathology, Institute of Psychiatry and Neurology, Warsaw, Poland, ²2nd Department of Neurology, Institute of Psychiatry and Neurology, Warsaw, Poland, ³Department of Neurosurgery, Institute of Psychiatry and Neurology, Warsaw, Poland

Folia Neuropathol 2012; 50 (2): 194-200

Abstract

We present two cases (female and male patients, aged 64 and 38, respectively) of focal mass lesions mimicking a brain tumour: one with cognitive function deficit, memory troubles, behavioral changes and left hemiparesis, the other with difficulty in orientation and right hemiparesis.

General physical and neurological examinations, laboratory tests and neuroimaging were used to diagnose the cases. Both of them showed nonspecific changes in the brain tissue and the brain tumour was suspected. In the first case MRI scan revealed two pathological masses in the right frontal region and hemorrhagic focus with destructions inside lesions. Second patient's MRI scan revealed a pathological mass at the interface of the left temporal and occipital regions. The neurosurgical procedure was performed. The final diagnosis was established on the basis of neuropathological examination of postoperative material. On light microscopy examination a severe cerebral amyloid angiopathy (CAA) was revealed. Amyloidoma was excluded due to the absence of amorphous material and eosynophylic masses.

Tumefactive CAA is a rare condition. These two cases of focal, tumefactive, masslike lesions of diffuse cerebral amyloid angiopathy are reported because of diagnostic dilemmas.

In patients with history of memory dysfunction, neurological deterioration and different multiple changes observed in CT and MRI scans, such as hemorrhagic infarcts and ischemic cerebral lesions, CAA should be suspected. The imaging findings make a distinction between tumefactive CAA and brain tumours like gliomas difficult. A differential diagnosis of CAA and amyloidoma plays a significant role in a neuropathological examination.

Key words: cerebral amyloid angiopathy (CAA), brain tumour, amyloidoma, intracerebral hemorrhage.

Introduction

Amyloid, a fibrillogenic product of the cell surface amyloid- β protein precursor (A β PP), comprising 39-43 amino acids, is not stored in the normal tissue [14]. Under pathologic circumstances, it is deposited in extracellular and intracellular spaces and generates amyloidosis.

Proteins or polypeptides form characteristic fine fibrils. Both systemic and tissue-specific depositions have been reported in humans. The factors that determine nodular versus diffuse amyloid accumulation remain uncertain. Amyloid deposits in the brain can take many forms such as senile plaques observed in Alzheimer's disease (AD), amyloid deposition associated with Down's syn-

Communicating author:

Aleksandra Karbowniczek, Department of Neuropathology, Institute of Psychiatry and Neurology, ul. Sobieskiego 9, 02-957 Warszawa, Poland, e-mail: aleksandra.karbowniczek@gmail.com

drome, fronto-temporal dementia, dementia with Lewy bodies, spongiform encephalitis and amyloid formations in advanced age. The least frequent one is amyloidoma presented as amorphous material of amyloid, mimicking a brain tumour in neuroimages. And finally a form of β -amyloid deposits in meningeal and cortical vessels defined as cerebral amyloid angiopathy (CAA) was found [1,13,17,25,31]. It is a common disorder in the brains of elderly demented and non-demented individuals. CAA primarily affects medium and small leptomeningeal arteries and cortical arterioles, less frequently veins and capillaries, occasionally subcortical vessels. The incidence and severity of CAA increase with age [6,7,13], and its severity is associated with cerebral haemorrhages, infarctions, and white matter lesions [2,21,31].

Three different mechanisms have been proposed for CAA [26]: derivation of $A\beta$ from blood and cerebrospinal fluid [35], production of $A\beta$ by smooth muscle cells within vessel walls and/or pericytes [27,33] and derivation of $A\beta$ from the neuropil in the course of its perivascular drainage [19,32].

Possession of at least one APOE e4 allele (APOE4) has been shown to be a risk factor for both CAA and AD [18,30].

There are very few reports of CAA presented as tumefactive mass lesions mimicking neoplasms. On non-enhanced CT scans, the amyloid material appears hyperattenuated [3,8,12,28] and shows enhancement after contrast. On MR images, the appearance is more variable. On T1-weighted images, amyloidomas can be hypointense [5], isointense [3], or hyperintense [15]. Despite the availability of advanced brain imaging technology, these conditions are difficult to ascertain without performing neuropathological examination [11].

Material and methods

The postoperative brain tissue material of both our patients was fixed in 4% paraformaldehyde in 0.1 M phosphorane-buffer saline and embedded in paraffin. The specimens were stained with HE, PAS, Congo Red methods and immunohistochemically using the following antibodies: neurofilaments (NFTs, Novocastra 1:50) and anti $A\beta$ 8-17 (DAKO 1 : 150). The prepared material was evaluated by light microscopy.

Presentation of cases and results

Patient 1

A 64-year-old woman was admitted to the Neurological Department with a new onset of difficulty in

orientation, cognitive function deficit, memory troubles and behavioural changes. Eighteen months earlier she had one episode with difficulty in reaching her son's house. The patient's mother and her sister had problems with memory. She had no risk factors for vascular diseases. Laboratory tests revealed only slight lipid abnormalities. The findings of admission physical examination were within normal limits, but a higher function testing revealed mild cognitive impairment (MCI) with 24 points in MMSE. She was treated with rivastigmine. MRI exam revealed two pathological masses, sized 38 × 35 mm and 22 × 22 mm, in the right frontal region, hemorrhagic focus with destructions inside lesions, slightly intensive with coexisting oedema and shifted median line, about 4 mm, on the opposite side (Figs. 1A, B). A primary brain tumour with haemorrhage into or brain abscess was suspected. She was qualified for surgery and taken to the Department of Neurosurgery. Craniotomy and tumour resection in the frontal and temporal regions on the right side was performed. Microscopic examination of the removed tissues revealed the presence of vessel wall thickening in the meningeal and intracerebral vessels (Figs. 3, 4) and positive immunohistochemical reactivity of β -amyloid in the meningeal (Fig. 5) and intracerebral (Figs. 5, 6) vessels. Severe CAA was found in the frontal lobe and typical findings characteristic of haemorrhage were diagnosed (Fig. 3). Amyloid plaques on the haemorrhage border could be observed (Fig. 6). Finally, the cerebral amyloid angiopathy was diagnosed. She was discharged home with a neurological deficit. In December 2009, she was readmitted to our Neurological Department due to increasing dementia – problems with memory, concentration and attention, and disturbances in visual coordination. MRI scan revealed postoperative cavum, sized 21 × 39 × 22 mm, in the right frontal lobe, multiple small ischemic lesions in the left frontal lobe and in both occipital lobes. MMSE was 20 points. Specialized genetic testing revealed that she is a heterozygous allele carrier with APOE e3/e4 genotype. She was discharged home. Her third admission (August 2010) to the Neurological Department was due to a sudden onset of left hemiparesis. Glasgow Coma Scale (GCS) was 6 points. A CT scan demonstrated hemorrhagic infarct, sized 44 × 15 mm, in the right hemisphere in the frontal and parietal regions. She was reoperated. The craniotomy of parietal right region was done with dissection of the hemorrhagic lesion. After two days, due to deterioration of consciousness, external ventricular drainage was performed because of

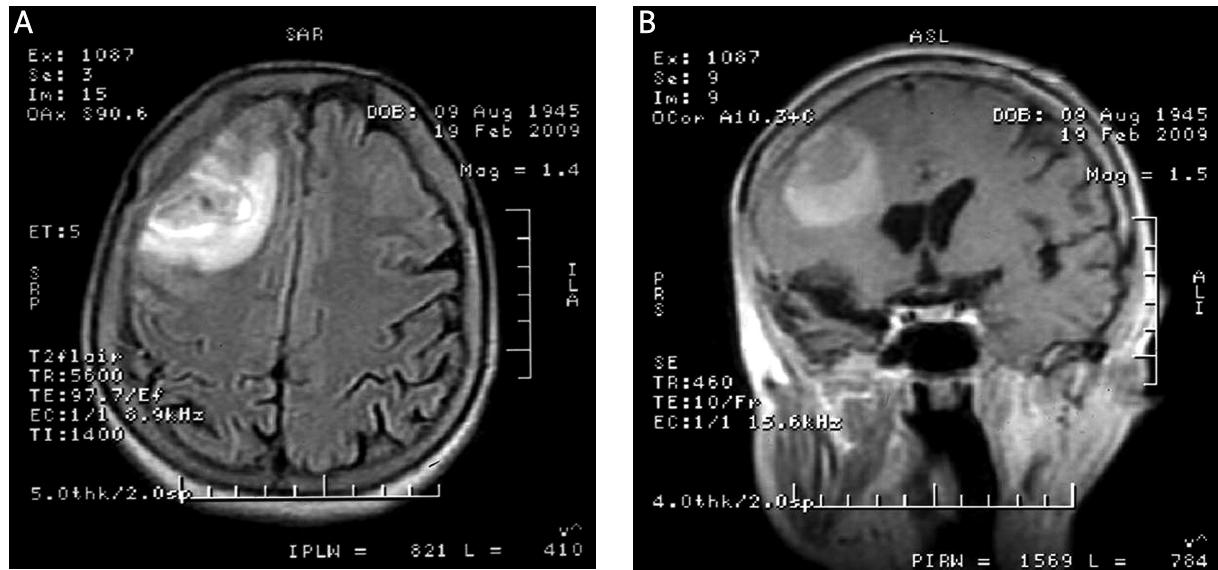


Fig. 1. Patient 1. **A)** MRI T2-Flair axial scan shows pathological mass sized 38 × 35 mm in the right frontal region, hemorrhagic focus with destructions inside. **B)** MRI T2-Flair coronal scan shows pathological mass with coexisting oedema and shifted median line about 4 mm to the opposite side.

hematoma (67 × 29 mm) with penetration into the ventricular system. Two weeks later she was oriented, with left hemiplegia, GCS was 14 points, and sent to the Neurological Rehabilitation Department. She was alert but somnolent, oriented only to her name and surname, with the presence of central nerve VII paresis, left side paresis, hemianesthesia, hemianopsia and hemineglect.

She was bedridden and she can sit. MMSE was 10 points. She was rehabilitated and her neurological status improved. She could stand under the supervision. She was discharged home using a wheelchair and needed constant care from her family members. Later on she had two epileptic seizures and carbamazepine was prescribed.

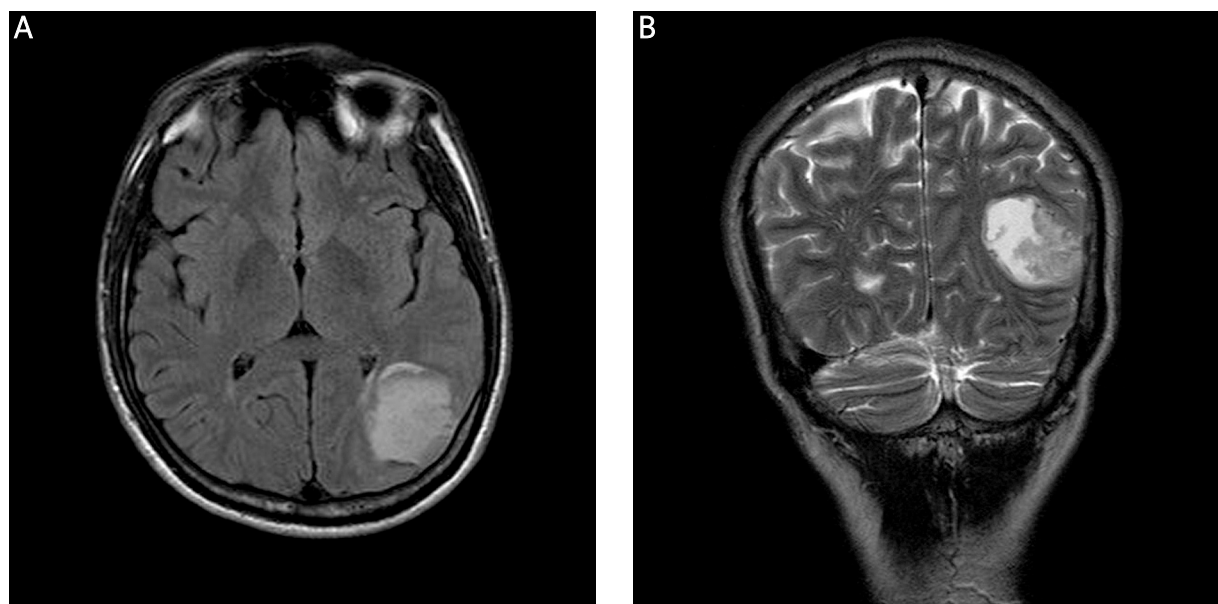


Fig. 2. Patient 2. **A)** MRI axial scan revealed contrast-enhanced mass sized 29 × 44 × 47 mm at the interface of the left temporal and occipital regions. **B)** MRI coronal scan of the same mass.

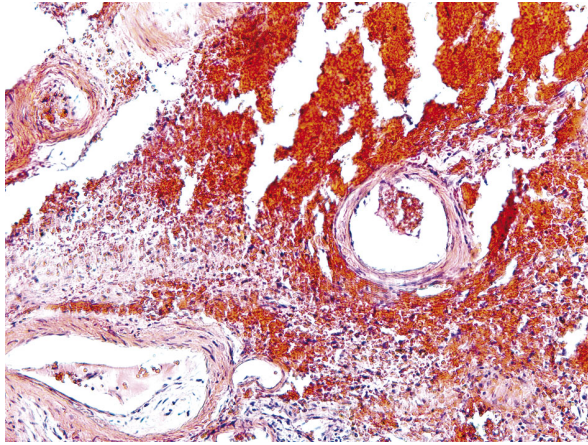


Fig. 3. Patient 1. Meningeal and parenchymal blood vessels variably thickened and surrounded by haemorrhage; HE \times 200.

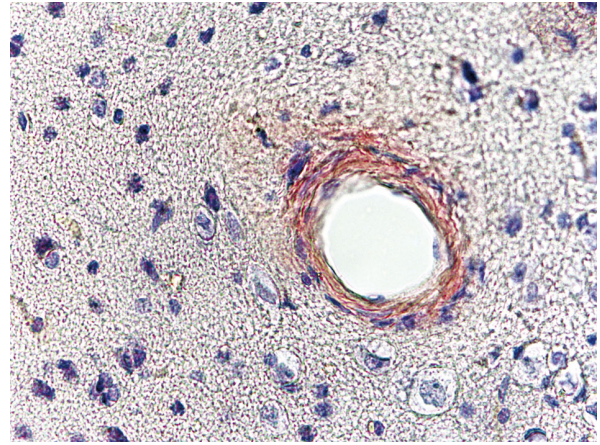


Fig. 4. Patient 1. Changes characteristic of CAA in vascular walls of intracerebral vessels; Congo red \times 200.

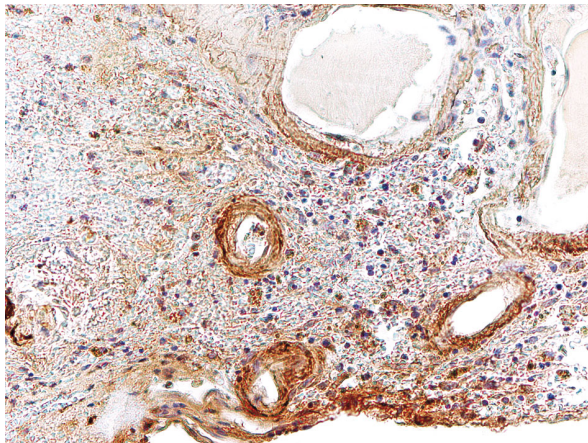


Fig. 5. Patient 1. Positive immunohistochemical reactivity of β -amyloid in the intracerebral and meningeal vessels; β -amyloid 8-17 \times 200.

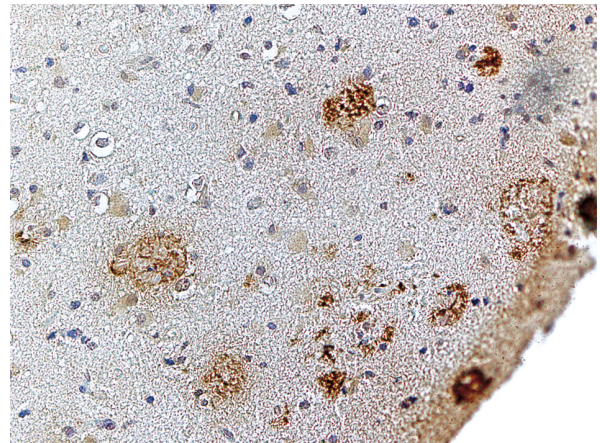


Fig. 6. Patient 1. Positive immunohistochemical reactivity of β -amyloid in the parenchymal vessels and amyloid deposits in the form of diffuse plaques; β -amyloid 8-17 \times 200.

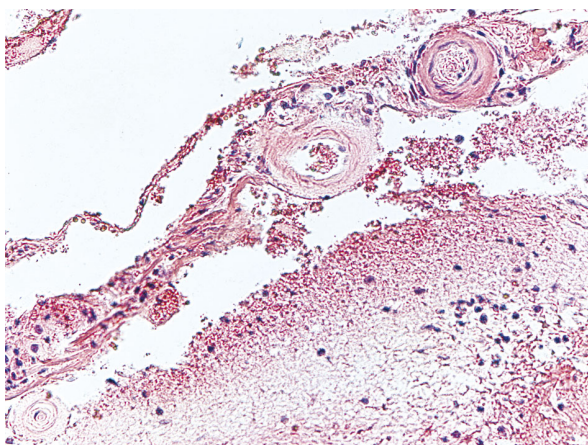


Fig. 7. Patient 2. Features of severe CAA in the walls of meningeal vessels; HE \times 200.

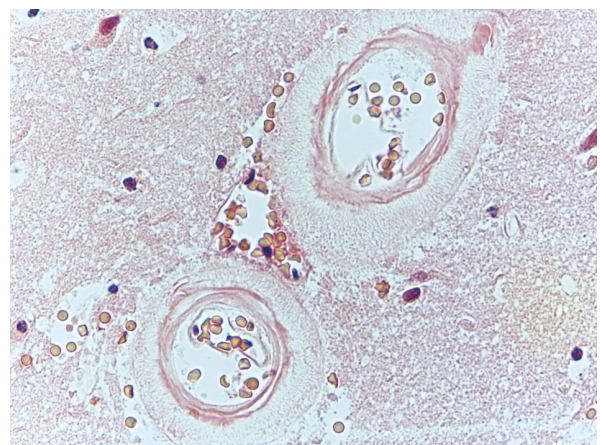


Fig. 8. Patient 2. The vessel wall replaced by eosinophilic hyaline material. "Double-barrel" of the vessel wall; HE \times 400.

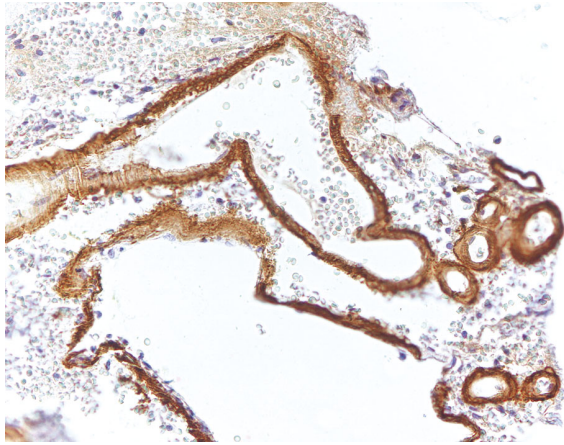


Fig. 9. Patient 2. Positive immunohistochemical reactivity of β -amyloid in the meningeal vessels; A β \times 200.

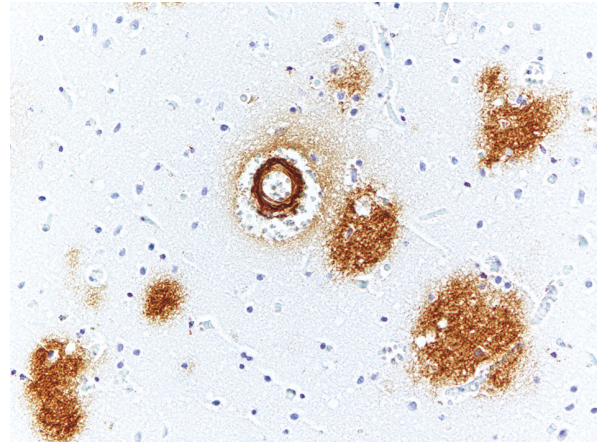


Fig. 10. Patient 2. Positive immunohistochemical reactivity of β -amyloid in the intracerebral vessels and amyloid deposits in the form of diffuse plaques; A β \times 400.

Patient 2

A 38-year-old man, with no medical history, was admitted to our Institution (September 2011) with a new onset of severe headache, difficulty in orientation and right hemiparesis. According to the family report, he also had problems with concentration and short-term memory. He had no family history of dementia or any neurological disorder. Laboratory tests were within normal limits. Neurological examination revealed right hemiambyopia, mild sensory aphasia, and positive Babinsky sign on the right side. Sensory aphasia increased during hospitalization. MRI exam revealed pathology enhanced by contrast mass, sized 29 \times 44 \times 47 mm, at the interface of the left temporal and occipital regions (Figs. 2A, B). Anti-oedematous treatment and high blood pressure treatment were included. Primary brain tumour was diagnosed. The patient was qualified for surgery and referred to the Neurosurgery Department. Craniotomy and resection of tumour in temporal and occipital regions on the left side were performed. Neuropathological examination of removed tissues revealed a bold outline of the vascular walls in meningeal and intracerebral vessels (Figs. 7, 8) and the presence of β -amyloid in vessels and amyloid diffusion plaques (Figs. 9, 10). Severe cerebral amyloid angiopathy was found in the temporo-occipital region. The Alzheimer plaques were revealed (Fig. 10). Finally, the cerebral amyloid angiopathy was diagnosed. Due to young age of the patient, a staging evaluation was performed, including a CT scan of the chest, abdomen and pelvis, to investigate systemic findings of amyloidosis.

The results of these tests were negative. He was discharged home without neurological deficit.

Discussion

Cerebral amyloid angiopathy denotes diffuse amyloid deposition in the brain that may occur with or without granulomatous inflammation and traditionally has not been thought to present as mass lesions. To our knowledge, there have been only few published cases of CAA, detailing the MR imaging findings of a tumour-like presentation [10,22-24,29]. A review of the previous and our cases shows that tumefactive mass lesions associated with CAA present with signal intensity increased at T2-weighted imaging and decreased at T1-weighted imaging without postcontrast enhancement. The imaging findings made the distinction between tumefactive CAA and primary brain tumours like low-grade gliomas difficult. In the literature, a tumour-like deposition is described as amyloidomas or CAA-tumour-like lesions. It should be underlined that histopathologically and radiographically, amyloidoma is a form of amyloid deposition that is distinct from tumefactive CAA. Whereas CAA refers to diffuse parenchymal deposition of amyloid with a focal mass-like lesion, amyloidoma is a focal deposition of amyloid with sparing of the remainder of the parenchyma. On histologic analysis, amyloidoma consists of brain tissue that is replaced by masses of amorphous eosinophilic material and scattered aggregates of plasma cells and lymphocytes [9,12,28]. The eosinophilic material is deposited in the majority of vessel walls as

well. Amyloidomas invariably show postcontrast enhancement, whereas tumefactive CAA usually does not exhibit contrast enhancement. MRI spectroscopy is a new tool in the diagnosis of CAA presenting as a brain tumour [11,20]. However, it was not performed in our patients.

In computed tomography and magnetic resonance imaging, a tumour-like deposition may be visible as amyloidoma composed of eosinophilic masses, Congo red and β -amyloid positive sections of abnormal vessels with dilated walls with amyloid and off vessels elements of blood called CAA. In the differential diagnosis, metastasis was also taken into account. Microscopic findings were typical of severe CAA and the absence of amorphous, eosinophilic material, lymphocytic and/or plasmatic cells infiltrations allowed for differential diagnosis. In both of our patients the final diagnosis was based on typical histological changes associated with progressive intellectual decline. CAA is known to be a risk factor for many recurrent intracerebral haemorrhages, as well as of ischemic necrosis, which led to the deterioration of the status and dementia in our male patient. In the female patient we were able to differentiate this case between CAA in vascular dementia and AD or mixed dementia. Vascular dementia can be indicated by the sudden onset of disease, second recurrence of symptoms one and a half years later and memory disturbance fluctuating over time. AD can be indicated by the fact that in anamnesis she had memory problems, progressing disease, neuropathological microscope exam and finally the diagnosed polymorphism of APOE. Chalmers *et al.* [4] reported that APOE4 frequency in AD patients is strongly related to the severity of CAA, but not to parenchymal A β , and concluded that APOE4 favours vascular over parenchymal accumulation of A β in AD, whereas Armstrong (2011) observed a weak correlation between APOE4 and parenchymal A β load (plaque score) [1,4]. Their findings do not support the data suggesting CAA to be an independent risk factor for cognitive decline, as it was significantly influenced by coexisting AD pathology [34]. In the young male patient, symptoms of dementia were not observed and the laboratory tests for APOE polymorphism was not performed. Due to the presence of amyloid plaques in neuropathological examination we cannot exclude the development of AD in both our patients.

Standard treatment of tumefactive CAA involves steroids and immunosuppressants. A few previous stud-

ies showed successful steroid therapy, while others showed successful treatment with immunosuppressants. Autopsy evidence suggests that immunosuppressive treatment decreases the amyloid burden [10,16,22]. In the presented patients, neurosurgery was performed as a first-line treatment because of the suspected primary brain tumour.

Conclusions

Cerebral amyloid angiopathy manifested as a brain tumour is a rare condition with many difficulties encountered in the diagnostic process. CAA should be suspected in patients with a history of memory dysfunction, neurological deterioration, different multiple changes, such as hemorrhagic infarcts and ischemic cerebral lesions, observed in CT and MRI scans. The imaging findings make a distinction between tumefactive CAA and brain tumours difficult. A differential diagnosis of CAA and amyloidoma plays a significant role in neuropathological examinations. Little is known about long-term effects in such patients as there are only few published reports with data going beyond five years [9].

References

1. Armstrong RA. Spatial patterns of β -amyloid (A) deposits in familial and sporadic Alzheimer's disease. *Folia Neuropathol* 2011; 49: 153-161.
2. Cadavid D, Mena H, Koeller K, Frommelt RA. Cerebral beta amyloid angiopathy is a risk factor for cerebral ischemic infarction. A case control study in human brain biopsies. *J Neuropathol Exp Neurol* 2000; 59: 768-773.
3. Caerts B, Mol V, Sainte T, Wilms G, Van Den Bergh V, Stessens L. CT and MRI of amyloidoma of the CNS. *Eur Radiol* 1997; 7: 474-476.
4. Chalmers K, Wilcock GK, Love S. APOE epsilon 4 influences the pathological phenotype of Alzheimer's disease by favouring cerebrovascular over parenchymal accumulation of A beta protein. *Neuropathol Appl Neurobiol* 2003; 29: 231-238.
5. Cohen M, Lanska D, Roessmann U, Roessmann B, Karaman E, Ganz E. Amyloidoma of the CNS, I: clinical and pathologic study. *Neurol* 1992; 42: 2019-2023.
6. Davis DG, Schmitt FA, Wekstein DR, Markesbery WR. Alzheimer neuropathologic alterations in aged cognitively normal subjects. *J Neuropathol Exp Neurol* 1999; 58: 376-388.
7. Ellis RJ, Olichney JM, Thal LJ, Mirra SS, Morris JC, Beekly D, Heyman A. Cerebral amyloid angiopathy in the brains of patients with Alzheimer's disease: the CERAD experience, Part XV. *Neurology* 1996; 46: 1592-1596.
8. Eriksson L, Sletten K, Benson L, Westermark P. Tumor-like localized amyloid of the brain is derived from immunoglobulin light chain. *Scand J Immunol* 1993; 37: 623-626.

9. Fischer B, Palkovic S, Rickett C, Weckesser M, Wassmann H. Cerebral AL lambda-amyloidoma: clinical and pathomorphological characteristics. Review of the literature and of a patient. *Amyloid* 2007; 14: 11-19.
10. Fountain NB, Eberhard DA. Primary angitis of the central nervous system associated with cerebral amyloid angiopathy. *Neurology* 1996; 46: 190-197.
11. Ghandi D, Wee R, Goyal M. CT and MR imaging of intracerebral amyloidoma: case report and review of the literature. *AJNR Am J Neuroradiol* 2003; 24: 519-522.
12. Hori A, Kitamoto T, Tateishi J, Hann P, Friede RL. Focal intracerebral accumulation of a novel type of amyloid protein. *Acta Neuropathol* 1988; 76: 212-215.
13. Jellinger KA. Alzheimer disease and cerebrovascular pathology: an update. *J Neural Transm* 2002; 109: 813-836.
14. Kowalska A. The hypothesis of β -amyloid cascade – a sequence of events leading to neurodegeneration in Alzheimer's disease. *Neurol Neurochir Pol* 2004; 38: 405-411.
15. Lee J, Krol G, Rosenblum M. Primary amyloidoma of the brain: CT and MR presentation. *AJNR Am J Neuroradiol* 1995; 16: 712-714.
16. Mandybur TI, Balko G. Cerebral amyloid angiopathy with granulomatous angitis ameliorated by steroid-cytotoxin treatment. *Clin Neuropharmacol* 1992; 15: 241-247.
17. Mendel T, Bertrand E, Szpak GM, Stępień T, Wierzbą-Bobrowicz T. Cerebral amyloid angiopathy as a cause of an extensive brain hemorrhage in adult patient with Down's syndrome – a case report. *Folia Neuropathol* 2010; 48: 206-211.
18. Mendel T, Gromadzka G. Polymorphism of apolipoprotein E gene (APOE) – the risk and prognosis of intracerebral haemorrhage caused by cerebral amyloid angiopathy. *Neurol Neurochir Pol* 2010; 44: 591-597.
19. Nicoll JA, Yamada M, Frackowiak J, Mazur-Kolecka B, Weller RO. Cerebral amyloid angiopathy plays a direct role in the pathogenesis of Alzheimer's disease. Pro-CAA position statement. *Neurobiol Aging* 2004; 25: 589-597.
20. Nossek E, Bashat D, Artzi M. The role of advanced MR methods in the diagnosis of cerebral amyloidoma. *Amyloid* 2009; 16: 94-98.
21. Olichney JM, Ellis RJ, Katzman R, Sabbagh MN, Hansen L. Types of cerebrovascular lesions associated with severe cerebral amyloid angiopathy in Alzheimer's disease. *Ann N Y Acad Sci* 2007; 826: 493-497.
22. Ortiz O, Reed L. Cerebral amyloid angiopathy presenting as a nonhemorrhagic, infiltrating mass. *Neuroradiology* 1996; 38: 449-452.
23. Osumi AK, Tien RD, Felsberg GJ, Rosenbloom M. Cerebral amyloid angiopathy presenting as a brain mass. *AJNR Am J Neuroradiol* 1995; 16 (4 Suppl): 911-915.
24. Polivka M, Vallat AV, Woimant F, Lot G, Boukobza M, Guichard JP, Mikol J. Cerebral amyloid angiopathy (CAA) with presentation as a brain inflammatory pseudotumour. *Clin Exp Pathol* 1999; 47: 303-310.
25. Preston SD, Steart PV, Wilkinson A, Nicoll JA, Weller RO. Capillary and arterial cerebral amyloid angiopathy in Alzheimer's disease: defining the perivascular route for the elimination of amyloid beta from the human brain. *Neuropathol Appl Neurobiol* 2003; 29: 106-117.
26. Revesz T, Ghiso J, Lashley T, Plant G, Rostagno A, Frangione B, Holtzman JL. Cerebral amyloid angiopathies: a pathologic, biochemical, and genetic view. *J Neuropathol Exp Neurol* 2003; 62: 885-898.
27. Revesz T, Ghiso J, Lashley T, Plant G, Rostagno A, Frangione B. Sporadic and familial cerebral amyloid angiopathies. *Brain Pathol* 2002; 12: 343-357.
28. Tabatabai G, Baehring J, Hochberg FH. Primary amyloidoma of the brain parenchyma. *Arch Neurol* 2005; 62: 477-480.
29. Vandermissen B, Salmon I, Hildebrand J. Recurrent nonhemorrhagic mass lesion due to cerebral amyloid angiopathy. *J Neurol* 2003; 250: 239-240.
30. Verghese Ph, Castellano J, Holtzman DM. Apolipoprotein E in Alzheimer's disease and other neurological disorders. *Lancet Neurol* 2011; 10: 241-245.
31. Vonsattel JP, Myers RH, Hedley-Whyte ET, Ropper AH, Bird ED, Richardson EP Jr. Cerebral amyloid angiopathy without and with cerebral hemorrhages: a comparative histological study. *Ann Neurol* 1991; 30: 637-649.
32. Weller RO, Nicoll JA. Cerebral amyloid angiopathy: pathogenesis and effects on the ageing and Alzheimer brain. *Neurol Res* 2003; 25: 611-616.
33. Wisniewski HM, Frackowiak J, Zoltowska A, Kim KS. Vascular beta-amyloid in Alzheimer's disease angiopathy is produced by proliferating and degenerating smooth muscle cells. *Int J Exp Clin Invest* 1994; 41: 8-16.
34. Zekry D, Duyckaerts C, Belmin J, Geoffre C, Moulins R, Hauw JJ. Cerebral amyloid angiopathy in the elderly: vessel walls changes and relationship with dementia. *Acta Neuropathol (Berl)* 2003; 106: 367-373.
35. Zlokovic BV, Ghiso J, Mackic JB, McComb JG, Weiss MH, Frangione B. Blood-brain barrier transport of circulating Alzheimer's amyloid beta. *Biochem Biophys Res Commun* 2003; 197: 1034-1040.