

# Lasting neuropathological changes in rat brain after intermittent neonatal administration of thimerosal

Mieszko Olczak<sup>1,2</sup>, Michalina Duszczyk<sup>1</sup>, Pawel Mierzejewski<sup>3</sup>, Teresa Wierzbą-Bobrowicz<sup>4</sup>, Maria Dorota Majewska<sup>1,5</sup>

<sup>1</sup>Marie Curie Chairs Programme at the Department of Pharmacology and Physiology of the Nervous System, Institute of Psychiatry and Neurology, Warsaw, Poland, <sup>2</sup>Department of Forensic Medicine, Medical University of Warsaw, Warsaw, Poland, <sup>3</sup>Department of Pharmacology and Physiology of the Nervous System, Institute of Psychiatry and Neurology, Warsaw, Poland, <sup>4</sup>Department of Neuropathology, Institute of Psychiatry and Neurology, Warsaw, Poland, <sup>5</sup>Department of Biology and Environmental Science, University of Cardinal Stefan Wyszyński, Warsaw, Poland

*Folia Neuropathol* 2010; 48 (4): 258-269

## Abstract

*Thimerosal, an organomercurial added as a preservative to some vaccines, is a suspected iatrogenic factor, possibly contributing to paediatric neurodevelopmental disorders including autism. We examined the effects of early postnatal administration of thimerosal (four i.m. injections, 12 or 240 µg THIM-Hg/kg, on postnatal days 7, 9, 11 and 15) on brain pathology in Wistar rats. Numerous neuropathological changes were observed in young adult rats which were treated postnatally with thimerosal. They included: ischaemic degeneration of neurons and “dark” neurons in the prefrontal and temporal cortex, the hippocampus and the cerebellum, pathological changes of the blood vessels in the temporal cortex, diminished synaptophysin reaction in the hippocampus, atrophy of astroglia in the hippocampus and cerebellum, and positive caspase-3 reaction in Bergmann astroglia. These findings document neurotoxic effects of thimerosal, at doses equivalent to those used in infant vaccines or higher, in developing rat brain, suggesting likely involvement of this mercurial in neurodevelopmental disorders.*

**Key words:** thimerosal, rat, brain, development, neuropathology.

## Introduction

Thimerosal (THIM; sodium ethylmercurithiosalicylate), containing approximately 49% mercury (Hg) by weight, has been used as a vaccine preservative since the 1930s. However, during the past decade serious concerns have emerged regarding its safety in infants, young children, and pregnant women. In the body THIM is metabolized to ethylmercury and subsequently to inorganic Hg forms [38], which accumu-

late in different organs/tissues including the brain, where they can remain for months or years [5,33]. Hundreds of years of human experience and thousands of scientific publications provide evidence of toxicity of mercurials, particularly severe for developing organisms [11,39,45]. With growing numbers of paediatric vaccines, many of which contained or still contain THIM in some countries, administered at ever younger age (e.g. Hep B vaccine is given during the first 24 h after birth in Poland, the U.S. and many

## Communicating author:

Maria Dorota Majewska, Department of Pharmacology and Physiology of the Nervous System, Institute of Psychiatry and Neurology, ul. Sobieskiego 9, 02-957 Warsaw, Poland, phone +48 22 458 27 78, fax +48 22 842 76 64, e-mail: majewska@ipin.edu.pl

other countries), infants have been exposed to increasing amounts of Hg, with potentially negative effects on their health. In fact, the years of the late 1980s and 1990s, when infants were exposed to the largest ever doses of Hg in vaccines, coincide with the emergence of epidemics of paediatric neurodevelopmental disorders, including autism [27,32].

Autism Spectrum Disorders (ASD) are characterized by a constellation of behavioural, psychiatric and neurological abnormalities, which include deficits in social interactions and communication, and motor dysfunction such as repetitive behaviours, accompanied by numerous neuroanatomical and biochemical abnormalities. Because many symptoms of autism resemble Hg poisoning, a hypothesis emerged linking this disorder with postnatal exposure to mercurials [4]. It was confirmed by several independent investigations [12,13,29,51], although it still remains controversial and requires further clinical and preclinical research.

Three independent preclinical studies examined neurodevelopmental toxicity of THIM, giving conflicting results. The study of Hornig *et al.* [17] and Laurent *et al.* [23] demonstrated neurotoxic actions of postnatal THIM administration in mice and hamsters, but the study of Berman *et al.* [3] failed to find such effects. We conducted a series of behavioural, neuropathological and neurochemical studies examining the neurotoxic actions of THIM, administered during the early postnatal period in rats. Our research revealed many neurobehavioural alterations in THIM-treated animals, such as impaired pain sensitivity and social interactions, locomotor deficits, and increased anxiety, which resemble symptoms of ASD [33] (additional manuscript in preparation), accompanied by dramatic changes in densities of mu opioid receptors in the brain [35]. Here we have focused on neuropathology and report enduring morphological alterations in brain tissues from neonatally THIM-exposed rats. A preliminary report of this work appeared in an abstract form [34].

## Material and methods

Pregnant Wistar rats were purchased from the Medical Research Centre, Polish Academy of Sciences, Warsaw, Poland. The animals were kept in a room under standard environmental conditions until breeding ( $22 \pm 1^\circ\text{C}$ , relative humidity 60%, 12 h-12 h light-dark cycle with lights on at 07:00 h). Standard laboratory chow (Labofeed H, WPIK, Poland) and tap water were available ad libitum. Newborn rats on postnatal days 7, 9, 11 and

15 received four equal-dose injections of THIM (Sigma-Aldrich) dissolved in saline in a volume of  $50 \mu\text{l}$ , i.m. into glutei maximi – this schedule was originally used in mice to mimic the infant immunization scheme [17]. The THIM doses per injection were 12 and  $240 \mu\text{g Hg/kg}$ . The lower dose is in the order of those used in multi-dose vaccine formulations in many countries [17,33]. Control rats received saline injections following the same scheme. Rats from one litter received the same treatment; there were four litters per experimental group. For neuropathological analyses, 10 animals per group (5 of each sex) were used, with at most 2 of each sex coming from the same litter. The remaining animals were used for other experiments. Control and THIM-treated rats at 8 weeks of age were sacrificed with overdose of i.p. pentobarbital injections, then decapitated. Brains were removed within 30 s, weighed, fixed in buffered formalin and embedded in paraffin for light microscope examination. All experiments were conducted according to the ethical standards laid down in respective Polish and European (directive No. 86/609/EEC) regulations. All procedures were reviewed and approved by the local ethics committee on animal studies.

The following brain structures were analysed: prefrontal cortex (bregma 4.68), temporal cortex (bregma 1.20), hippocampus (bregma  $-3.84$ ), and cerebellum (bregma  $-11.00$ ). The position of the regions was determined according to the rat brain atlas [37]. Slices showing above brain regions were stained histologically (haematoxylin-eosin) and immunohistochemically with: Rabbit Polyclonal Antibody to Active Caspase-3 (Abcam, 1 : 50), Lyophilized Mouse Monoclonal Antibody to Glial Fibrillary Acidic Protein (Novocastra, 1 : 100), and Synaptophysin Lyophilized Mouse Monoclonal Antibody (Novocastra, 1 : 100).

Microphotographs of the brain sections were taken with an Olympus BX41 microscope and Olympus DP25 digital camera. Images were saved in TIFF format. For each experiment, microphotographs were taken with the same light level for all sections. To evaluate the synaptophysin reaction, as a putative marker of synaptic density, sections showing the hippocampus (CA3 field) were analysed. Microphotographs of each region were taken from both cerebral hemispheres with magnification of 200 (area  $141\,808.92 \mu\text{m}^2$ ). The synaptic density/synaptophysin vesicular content was counted as a stained area fraction in the analysed region, with ImageJ 1.41o software and used for statistical analysis. Area fraction was automatically counted with the “Threshold” function of the ImageJ program, which

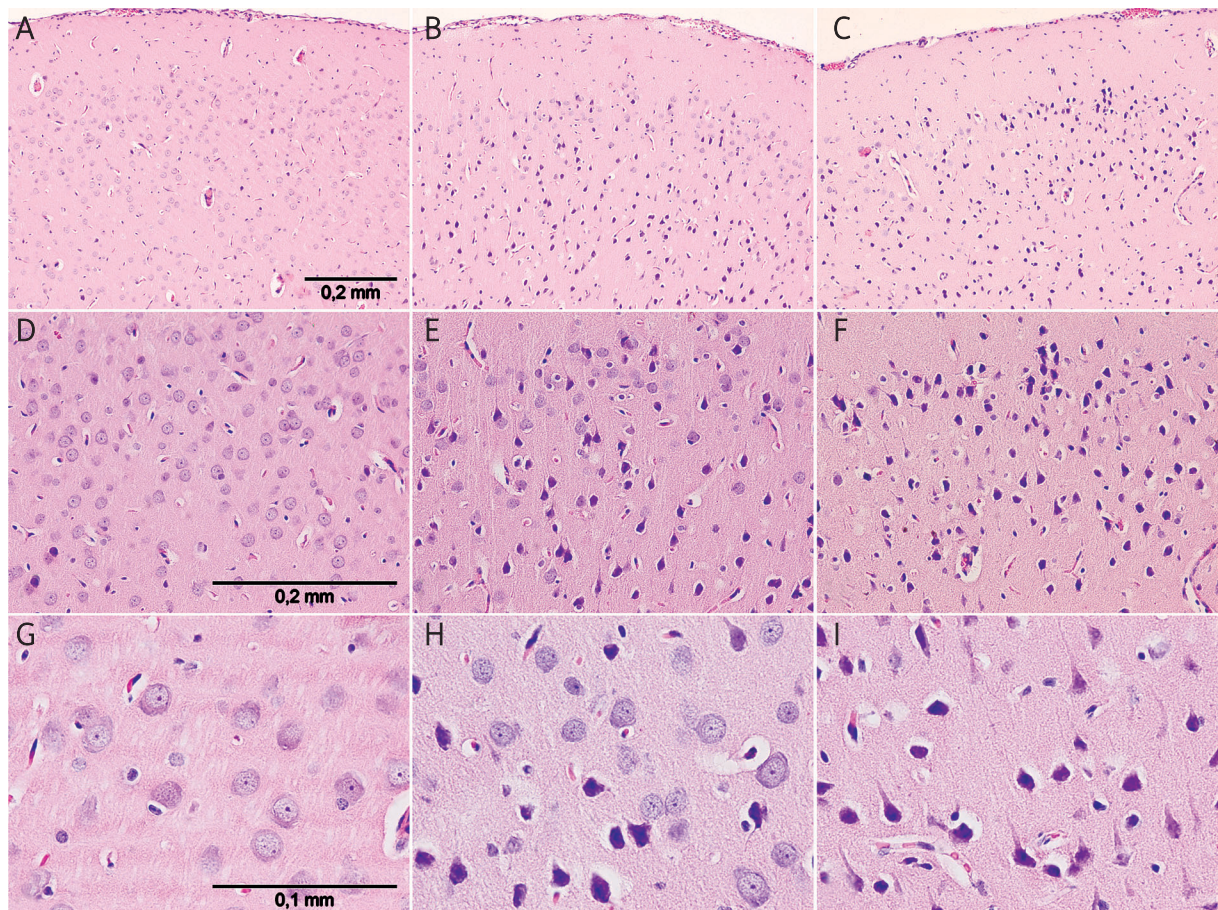
marks all the pixels of a selected grey value and counts all the groups of marked pixels (e.g. positive synaptophysin reaction) within the selected area [1]. Two corresponding areas from opposite hemispheres per animal per structure were analysed. Values from each side and structure were averaged for each animal and used for statistical analysis.

## Results

The brain weights of 8-week old control and postnatally THIM-treated rats were compared ( $N = 5$  per group/sex). For the control group, the mean brain weight for males was  $1.745 \pm 0.016$  g and for females  $1.671 \pm 0.035$  g. For THIM dose  $12 \mu\text{g Hg/kg}$ , the mean brain weight for males was  $1.731 \pm 0.021$  g and for females  $1.633 \pm 0.008$  g; for THIM dose  $240 \mu\text{g Hg/kg}$  for males it was  $1.793 \pm 0.014$  g and for females  $1.661$

$\pm 0.020$  g. Two-way ANOVA (Hg dose  $\times$  sex) revealed a non-significant effect of Hg dose ( $F[2.23] = 2.84$ ;  $p = 0.08$ ), a non-significant interaction sex  $\times$  Hg dose ( $F[2.23] = 1.09$ ;  $p = 0.35$ ), but a significant effect of sex ( $F[1.23] = 41.0$ ;  $p < 0.001$ ). The data show no significant effect of THIM treatment on brain weight, with a possible trend of a small (3%) increase in male rats treated with a THIM dose of  $240 \mu\text{g Hg/kg}$ .

The prefrontal and temporal cortex of neonatally THIM-treated rats manifested ischaemic degeneration of neurons and “dark” neurons (markedly shrunken and hyperchromatic) [20,28]. These changes were seen predominantly in the 2<sup>nd</sup> and 3<sup>rd</sup> layers of the prefrontal cortex and were more pronounced in animals treated with the higher THIM dose. Some groups of neurons were unaffected. Neurons in the control group appeared normal (Fig. 1). In analysed regions of



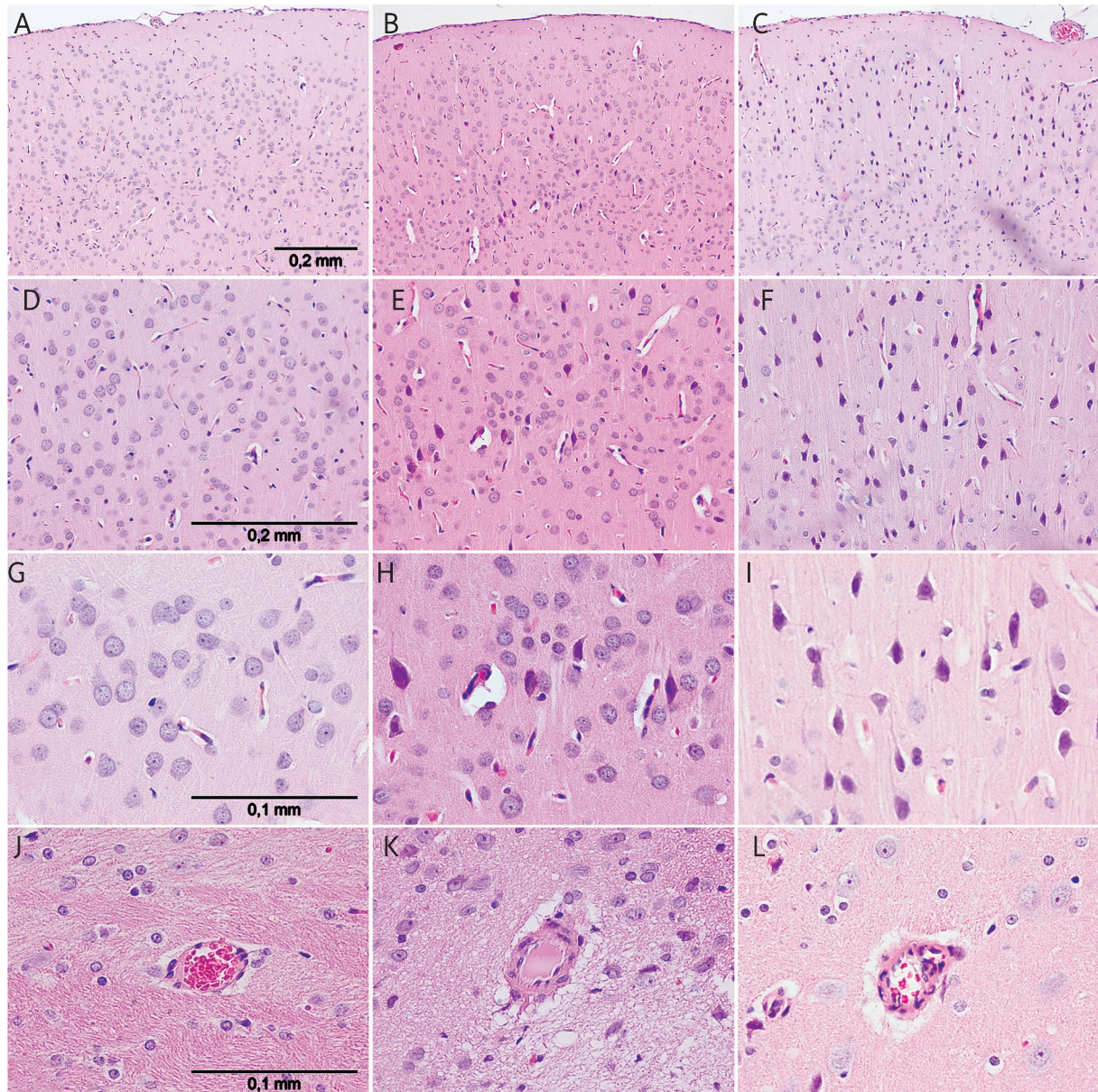
**Fig. 1.** Pathological changes in the prefrontal cortex after postnatal THIM treatment; 8-week old male rats; HE staining. Hg dose: **A, D, G** control group; **B, E, H** –  $12 \mu\text{g Hg/kg}$ ; **C, F, I** –  $240 \mu\text{g Hg/kg}$ . In THIM-treated animals ischaemic degeneration of neurons and “dark” neurons are visible (more prominent with higher THIM dose); magnification: **A-C**  $\times 100$ ; **D-F**  $\times 200$ ; **G-I**  $\times 400$ .



the prefrontal and temporal cortex, there were no distinctions in pathological features between males and females (only males are shown) and no obvious differences in the appearance of astroglia, or caspase-3 and synaptophysin reactions, between the control and THIM-treated groups. Ischaemic degeneration of neurons in the temporal cortex of THIM-exposed rats

was accompanied by pathological changes of the blood vessels, manifested by proliferation of the endothelium and thickened vascular walls. Control animals showed normal vascular morphology (Fig. 2).

Similar ischaemic degeneration of neurons and “dark” neurons were observed in the dorsal hippocampus (bregma  $-3.60$ ) of THIM-treated rats. The neu-



**Fig. 2.** (Pictures A-I) Pathological changes in the temporal cortex after postnatal THIM administration; 8-week old male rats; HE staining. Hg dose: **A, D, G, J** control group; **B, E, H, K** – 12 µg Hg/kg; **C, F, I, L** – 240 µg Hg/kg. In THIM-treated animals ischaemic degeneration of neurons and “dark” neurons are visible (more prominent at higher THIM dose). (Pictures J-L) Changes in the blood vessels in the temporal cortex after THIM treatment; 8-week old rats; HE staining; magnification: A-C  $\times 100$ ; D-F  $\times 200$ ; G-L  $\times 400$ .

ropathological changes were present in the granular layer of the dentate gyrus, CA1 and CA3 fields; they were more prominent in the animals treated with a higher THIM dose. The neurons in the control group looked normal (Fig. 3). The pathological changes in analysed regions of the hippocampus were similar in both sexes. There were no apparent differences in hippocampal blood vessels and caspase-3 reaction between the control and THIM-exposed animals.

In the hippocampus, degenerative changes in neurons of THIM-treated rats were not accompanied by reactive astrogliosis; instead pathological alterations in the astroglia were noted. In the regions of ischaemic degenerated neurons and in adjacent areas, contracted astrocytes with clasmatodendrosis were observed. Pathological changes in hippocampal astroglia were seen in tissues from rats treated with both doses of THIM. The astroglia in the control group appeared normal (Fig. 4). The THIM-induced alterations in hippocampal neurons and astroglia were accompanied by a significant loss of synaptophysin marker, suggesting reduction of synaptic density or synaptophysin concentration in synaptic vesicles. For the synaptophysin reaction in the CA3 field the two way ANOVA (sex  $\times$  Hg dose) revealed: a significant effect of dose ( $F[2,24] = 12.323$ ;  $p < 0.001$ ), a non-significant effect of sex ( $F[1,24] = 0.5503$ ;  $p = 0.6$ ), and a non-significant interaction sex  $\times$  dose ( $F[2,24] = 0.674$ ;  $p = 0.519$ ). The *post-hoc* (LSD) analysis confirmed significance of the dose effect for a THIM dose of 12  $\mu\text{g}$  Hg/kg, for males ( $p = 0.05$ ) and for females ( $p = 0.001$ ); and for a dose of 240  $\mu\text{g}$  Hg/kg for males ( $p = 0.012$ ) and for females ( $p = 0.001$ ) (Fig. 4; Table I).

The cerebellum (Bregma  $-11.04$ ) of THIM-treated rats showed ischaemic degeneration of single neurons in the granular and molecular layers. Also changes in the Purkinje cell layer were noted, with Purkinje neurons manifesting ischaemic and homogenizing degeneration (Fig. 5). There was no proliferation of Bergmann astroglia next to degenerating Purkinje cells; rather atrophy of these cells was seen in tissues from THIM-treated rats (Fig. 6). Neuropathological changes were more distinct in the lateral cerebellar lobules than in the central area and were more pronounced at the higher THIM dose. In the cerebellum from THIM-treated rats, degenerating Purkinje cells and atrophied Bergmann astroglia were accompanied by a positive caspase-3 reaction among Bergmann astroglial cells (Fig. 6), suggesting cell damage [26,30,46]. In the control group, neurons in

granular and molecular layers, the Purkinje cells and the astroglia were normal.

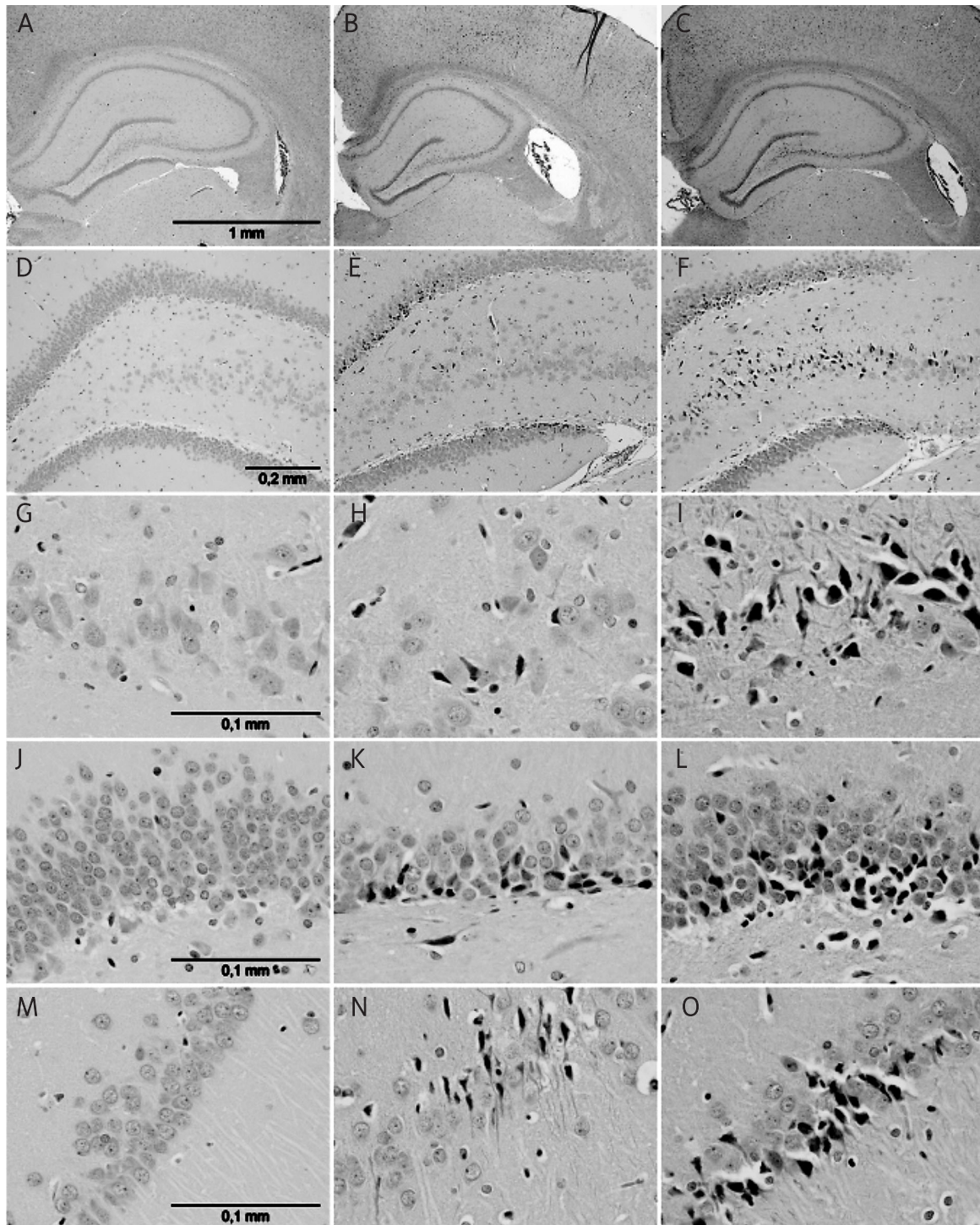
## Discussion

In previous publications we described behavioural and neurochemical anomalies in rats which in the early postnatal period received four vaccination-like THIM injections [33-35]. Some changes (impaired pain reaction, dysfunctional opioid system, locomotor deficits, enhanced anxiety) appeared already at the THIM dose of 12  $\mu\text{g}$  Hg/kg, which is in the order of doses still present in some paediatric vaccines. Here we report widespread neuropathological changes in brains of rats which received postnatal THIM injections at doses of 12  $\mu\text{g}$  Hg/kg or higher.

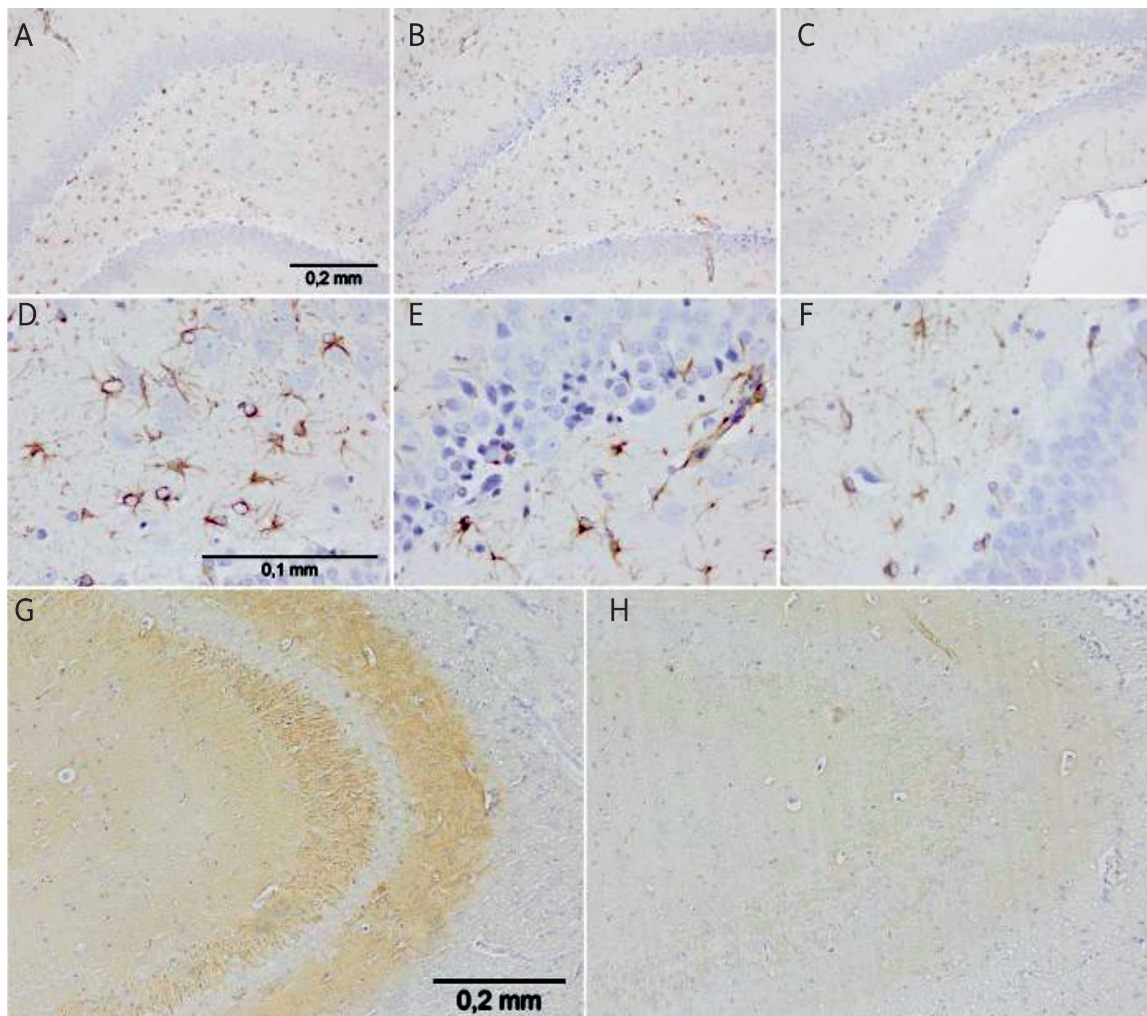
Administration of THIM at a dose of 12  $\mu\text{g}$  Hg/kg did not seem to disturb pups' overall physical development, although in the 8-week old male rats treated with a THIM dose of 240  $\mu\text{g}$  Hg/kg, a trend for a non-significant increase (3%) of brain weight was noted. Nonetheless, the brains of male and female rats treated with both THIM doses manifested numerous pathological changes such as: ischaemic degeneration of neurons and "dark" neurons in the prefrontal and temporal cortex and in the hippocampus, and homogenizing and ischaemic degeneration of Purkinje cells in the cerebellum [7,28]. These alterations were not accompanied by visible signs of astrogliosis, but rather by astroglia atrophy in some brain regions (the hippocampus and cerebellum). Blood vessel pathology with endothelial proliferation and thickened vessel walls was seen in the temporal cortex, while a positive caspase-3 reaction, suggestive of apoptosis, was noted in the Bergman astroglia.

To the best of our knowledge, this is the first report of pervasive neuropathological changes in brains of rats exposed neonatally to THIM doses equivalent to those used in vaccines, although various neuropathological changes have previously been described in mice [17] and hamsters [23] treated with THIM at the neonatal stage. THIM's neurotoxicity was also reported in isolated neurons *in vitro*: nanomolar THIM concentrations caused death by apoptosis or necrosis [18,49], with nerve growth factor (NGF) and low molecular thiols providing some protection [36,52]. Neuronal death mostly by apoptosis was also found in brains of rats exposed to methylmercury [31]. Although in our experiments a marker of apoptotic cells (positive caspase-3 reaction) was detected only





**Fig. 3.** Pathological changes in the dorsal hippocampus after postnatal THIM administration; 8-week old male rats; HE staining. Hg doses: **A, D, G, J, M** – control group; **B, E, H, K, N** – 12  $\mu\text{g}$  Hg/kg; **C, F, I, L, O** – 240  $\mu\text{g}$  Hg/kg. Structures: **A-O** dorsal hippocampus; **A-C** general view; **D-F** dentate gyrus and CA4 field; **G-I** CA3 field; **J-L** dentate gyrus; **M-O** CA1 field. In THIM-treated groups, ischaemic degeneration of neurons and “dark” neurons are visible in the dentate gyrus, CA1 and CA3 fields (changes more prominent with higher THIM dose). No obvious changes in the granular layer thickness in THIM-treated animals compared to control group were observed; magnification: **A-C**  $\times 40$ ; **D-F**  $\times 100$ ; **G-O**  $\times 400$ .

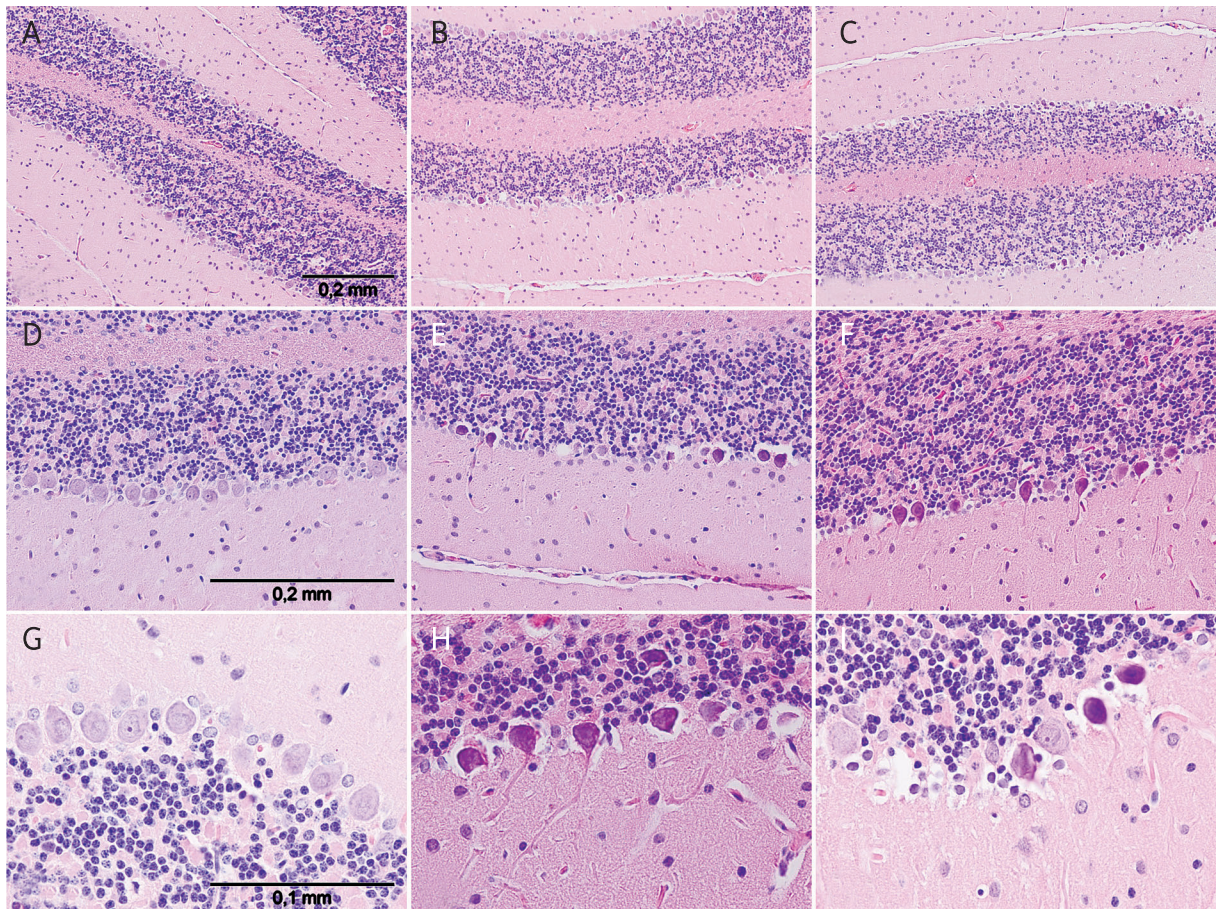


**Fig. 4.** Glial and synaptic pathology in the hippocampus of neonatally THIM-treated animals. (Pictures **A-F**) Changes in the astroglia of the dentate gyrus after THIM administration; 8-week old rats; GFAP reaction. Hg doses: **A, D** – control group; **B, E** – 12 µg Hg/kg; **C, F** – 240 µg Hg/kg. Contracted astrocytes with fragmentation of their processes without visible astroglia proliferation are observed in tissues from THIM-treated animals (changes more prominent with higher THIM dose). (Pictures **G-H**) Diminished synaptophysin reaction in the dorsal hippocampus after postnatal THIM administration; synaptophysin reaction. Hg dose: **G** – control group, **H** – 240 µg Hg/kg; magnification: A-C × 100; D-F × 400; G-H × 100.

**Table I.** Effect of postnatal THIM administration on synaptic density (synaptophysin reaction) in the hippocampus' CA3 field in 8-week old rats. THIM dose is given in µg Hg/kg. AV-AF – average stained area fraction (in %) of positive synaptophysin reaction in the hippocampus' CA3 field (Fig. 4; pictures G and H). % CTRL – percent of control value; *p* – significance

Hg dose µg/kg	Males				Females			
	AV-AF	± SEM	<i>p</i>	% CTRL	AV-AF	± SEM	<i>p</i>	% CTRL
0	3.888	0.195	x	100	4.936	1.276	x	100
12	2.055	0.427	0.050	53	1.654	0.473	0.001	34
240	1.500	0.382	0.012	39	1.666	0.392	0.001	34





**Fig. 5.** Pathological changes in the cerebella in postnatally THIM-treated, 8-week old rats; HE staining. Hg dose: **A, D, G** – control group; **B, E, H** – 12 µg Hg/kg; **C, F, I** – 240 µg Hg/kg. Changes in the Purkinje cell layer, such as ischaemic and homogenizing degeneration of Purkinje neurons, were observed (changes more prominent with higher THIM dose); magnification: **A-C** × 100; **D-F** × 200; **G-H** × 400.

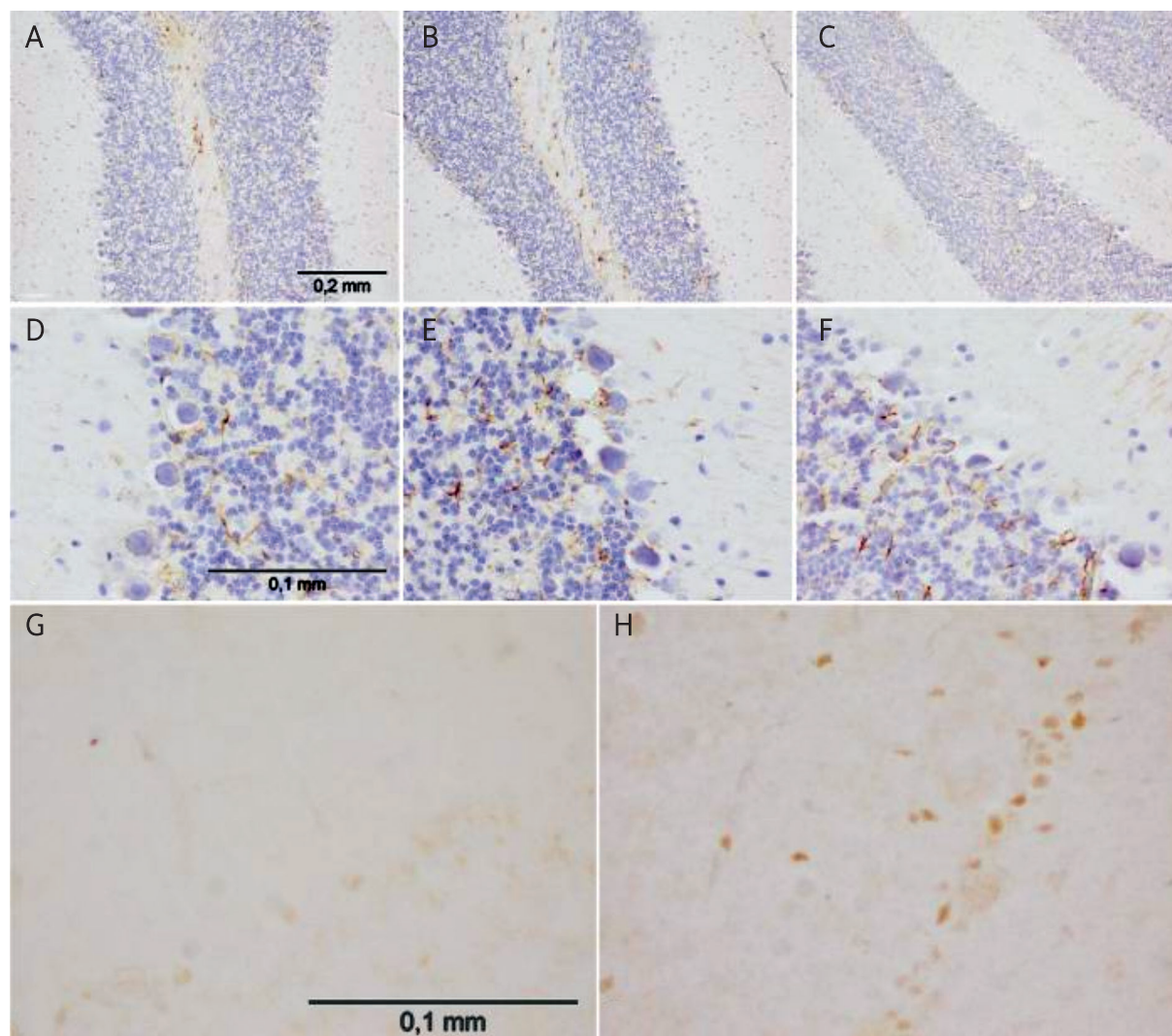
in the Bergmann glia, apoptotic processes in neural cells in other brain regions cannot be excluded. In fact, apoptosis in absence of caspase-3 activation was described in the neonatal cerebellar granule cells [24], methylmercury was found to induce apoptosis without caspase-3 activation in cultured cerebellar neurons [48], and oxidative stress was shown to trigger programmed cell death independently of caspase-3 activation in cortical neurons [16].

THIM-induced neuronal death by apoptosis or necrosis may depend on many intra- and extracellular factors, including concentrations of Hg in distinct cellular compartments at different periods after THIM injections, animal developmental stage, availability of neuroprotective molecules such as NGF, glutathione, -SH containing amino acids, peptides and proteins, antioxidants, hormones, and other factors which might

modulate its toxicity. Ischaemic appearance of many degenerating neurons in THIM-exposed rats is consistent with brain lesions observed in patients with Minamata disease (methylmercury poisoning). Takeuchi [47] described two major mechanisms of injury to brain cortex by methylmercury: a direct toxic effect – stronger on neuronal than on glial and epithelial cells – and a hypoxaemic/anoxaemic effect, resulting from the disturbance of blood circulation and perivascular oedema. Disseminated brain ischaemic areas and oedema were also observed in humans and marmosets exposed to methylmercury [9,10]. Neural cell death may additionally ensue from mercurial-induced DNA damage [2] and mitochondrial injury, leading to bioenergetic crisis and oxidative stress [44,50].

While discussing the issue of developmental THIM neurotoxicity, it is important to take into considera-





**Fig. 6.** Changes in the cerebellar astroglia in neonatally THIM-treated rats, 8-week old rats; GFAP reaction. Hg dose: **A, D** – control group; **B, E** – 12 µg Hg/kg; **C, F** – 240 µg Hg/kg; Bergmann astroglia atrophy without astroglia proliferation was observed in THIM-treated rats (changes more prominent with higher THIM dose). (Pictures **G-H**) Cerebellum, anti-caspase-3 reaction. Hg doses: **G** – control group; **H** – 240 µg Hg/kg. Positive caspase-3 reaction was observed in the Bergmann’s astroglia of THIM-treated animals; magnification: **A-C** × 100, **D-H** × 400.

tion the probable brain concentrations of Hg. In our experiments, neuropathological examinations were conducted six weeks after administration of the last dose of THIM. A pharmacokinetic experiment showed that Hg from THIM injections persists in the rat brain for many weeks/months, suggesting that at the time of pathological evaluations and earlier its brain concentrations could have been in the nanomolar range [33], which elicits neurotoxic effects [18,36,49,52]. The neurotoxic actions of THIM may evolve in two

phases. The early phase of acute neuronal toxicity may take place a few hours/days after THIM injection, when brain Hg concentrations are highest and when ischaemic degeneration of neurons and homogenizing degeneration of Purkinje cells may occur. The later, more extended, phase may ensue from chronic poisoning of neurons by accumulated Hg (seen as “dark neurons”). In rats, the second postnatal week (when THIM was administered) is an active neurodevelopmental period, characterized by continuing neu-

ral cell proliferation, migration, synaptogenesis, apoptosis, gliogenesis and myelinization, particularly dynamic in the hippocampus and the cerebellum [19,21,40,43]. Mercurials' interference with neurogenesis, gliogenesis, apoptosis and probably with other of these processes is likely to have significant neurodevelopmental consequences [6,11].

It is intriguing that THIM-induced neuronal degeneration was not accompanied by reactive astrogliosis, but rather by astrocytic atrophy seen in the hippocampus and cerebellum. Such a neuropathological pattern seems distinct from that reported after chronic postnatal rat exposure to methylmercury, where loss of neurons in the cerebral cortex and cerebellum was associated with astrocytosis [42]. Also in adult humans chronically poisoned with methylmercury neuronal loss in the cerebral cortex and cerebellum was accompanied by proliferation of astroglia [8]. It remains to be elucidated why postnatal THIM administration does not lead to similar changes. It might potentially be due to the different mode of mercurial administration, to an inhibitory effect of ethylmercury on cell proliferation, or its frank toxicity to developing astrocytes [44]. THIM-induced injury to astroglia may have critical neuropathological consequence for developing organisms, as protoplasmic processes of glial cells are the matrix for the central nervous system, participate in neuron migration, create the blood-brain barrier, keep the neurotransmitters in synapses and participate in metabolism of neurotransmitters such as glutamate, GABA or serotonin [14,22]. Neuropathological alterations such as loss of neurons without astroglia proliferation suggest an impact on terminal stages of postnatal gliogenesis. This issue requires further studies.

**In conclusion**, the present study documents that administration of THIM to suckling rats in a vaccination-like manner and at doses analogous to those used in paediatric vaccines or higher injures neurons and astroglia in several brain regions. These findings may be extrapolated (with caution) to certain clinical conditions, since THIM and other mercurials are suspected pathogenic factors in the aetiology of several neurodevelopmental disorders, including autism [12,13,15,25,29,41,51]. Some neuropathologies, such as morphological and neuroanatomical changes in the prefrontal and temporal cortex, or loss of Purkinje cells, seem common for THIM's neurotoxic actions and these disorders. While this study has obvious limitations, it provides clear evidence of neurotoxicity of

pharmacologically relevant doses of THIM in developing organisms, lending further support to the hypothesis implicating mercurials in paediatric neurodevelopmental disorders. On the whole, the results of this study argue for urgent removal of THIM from all vaccines for children and pregnant women, as well as from other medicinal products and cosmetics.

## Acknowledgements

We are grateful to Ms. Kinga Ode, Joanna Młynarczyk and Barbara Dąbrowska for skilful technical assistance. This publication is a part of the ASTER project funded by a European Commission grant (MEXC-CT 2006-042371) and by supplementary funding from the Ministry of Science and Higher Education of Poland – both to Maria Dorota Majewska.

## References

1. Anderson BD, Nakamura T, Russell SJ, Peng KW. High CD46 receptor density determines preferential killing of tumor cells by oncolytic measles virus. *Cancer Res* 2004; 64: 4919-4926.
2. Baskin DS, Ngo H, Didenko VV. Thimerosal induces DNA breaks, caspase-3 activation, membrane damage, and cell death in cultured human neurons and fibroblasts. *Toxicol Sci* 2003; 74: 361-368.
3. Berman RF, Pessah IN, Mouton PR, Mav D, Harry J. Low-level neonatal thimerosal exposure: further evaluation of altered neurotoxic potential in SJL mice. *Toxicol Sci* 2008; 101: 294-309.
4. Bernard S, Enayati A, Redwood L, Roger H, Binstock T. Autism: a novel form of mercury poisoning. *Med Hypotheses* 2001; 56: 462-471.
5. Burbacher TM, Shen DD, Liberato N, Grant KS, Cernichiari E, Clarkson T. Comparison of blood and brain mercury levels in infant monkeys exposed to methylmercury or vaccines containing thimerosal. *Environ Health Perspect* 2005; 113: 1015-1021.
6. Burke K, Cheng Y, Li B, Petrov A, Joshi P, Berman RF, Reuhl KR, DiCicco-Bloom E. Methylmercury elicits rapid inhibition of cell proliferation in the developing brain and decreases cell cycle regulator, cyclin E. *Neurotoxicology* 2006; 27: 970-981.
7. Dymecki J, Kulczycki J. *Neuropatologia*. Urban & Partner, Wrocław 2005; pp: 59-79.
8. Eto K, Takizawa Y, Akagi H, Haraguchi K, Asano S, Takahata N, Tokunaga H. Differential diagnosis between organic and inorganic mercury poisoning in human cases – the pathologic point of view. *Toxicol Pathol* 1999; 27: 664-671.
9. Eto K, Yasutake A, Kuwana T, Korogi Y, Akima M, Shimozeki T, Tokunaga H, Kaneko Y. Methylmercury poisoning in common marmosets – a study of selective vulnerability within the cerebral cortex. *Toxicol Pathol* 2001; 29: 565-573.



10. Eto K, Tokunaga H, Nagashima K, Takeuchi T. An autopsy case of minamata disease (methylmercury poisoning) – pathological viewpoints of peripheral nerves. *Toxicol Pathol* 2002; 30: 714-722.
11. Falluel-Morel A, Sokolowski K, Sisti HM, Zhou X, Shors TJ, Dicicco-Bloom E. Developmental mercury exposure elicits acute hippocampal cell death, reductions in neurogenesis, and severe learning deficits during puberty. *J Neurochem* 2007; 103: 1968-1981.
12. Gallagher C, Goodman M. Hepatitis B triple series vaccine and developmental disability in US children aged 1-9 years. *Toxicol Environ Chem* 2008; 90: 997-1008.
13. Geier DA, Geier MR. A meta-analysis epidemiological assessment of neurodevelopmental disorders following vaccines administered from 1994 through 2000 in the United States. *Neuro Endocrinol Lett* 2006; 27: 401-413.
14. Hagg T. Molecular regulation of adult CNS neurogenesis: an integrated view. *Trends Neurosci* 2005; 8: 589-595.
15. Hewitson L, Lopresti BJ, Stott C, Mason NS, Tomko J. Influence of pediatric vaccines on amygdala growth and opioid ligand binding in rhesus macaque infants: A pilot study. *Acta Neurobiol Exp (Wars)* 2010; 70: 147-164.
16. Higgins GC, Beart PM, Nagley P. Oxidative stress triggers neuronal caspase-independent death: endonuclease G involvement in programmed cell death-type III. *Cell Mol Life Sci* 2009; 66: 2773-2787.
17. Hornig M, Chian D, Lipkin WI. Neurotoxic effects of postnatal thimerosal are mouse strain dependent. *Mol Psychiatry* 2004; 9: 833-845.
18. Humphrey ML, Cole MP, Pendergrass JC, Kinningham KK. Mitochondrial mediated thimerosal-induced apoptosis in a human neuroblastoma cell line (SK-N-SH). *Neurotoxicology* 2005; 26: 407-416.
19. Jacobson, M. *Developmental Neurobiology*. 2nd ed. Plenum, New York 1991, pp. 41-93.
20. Kövesdi E, Pál J, Gallyas F. The fate of “dark” neurons produced by transient focal cerebral ischemia in a non-necrotic and non-excitotoxic environment: neurobiological aspects. *Brain Res* 2007; 1147: 272-283.
21. Kuhn HG, Dickinson-Anson H, Gage FH. Neurogenesis in the dentate gyrus of the adult rat: age-related decrease of neuronal progenitor proliferation. *J Neurosci* 1996; 16: 2027-2033.
22. Laming PR, Kimelberg H, Robinson S, Salm A, Hawrylak N, Müller C, Roots B, Ng K. Neuronal-glia interactions and behaviour. *Neurosci Biobehav Rev* 2000; 24: 295-340.
23. Laurente J, Remuzgo F, Ávalos B, Chiquinta J, Ponce B, Avendaño R, Maya L. Neurotoxic effects of thimerosal at vaccine doses on the encephalon and development in 7 days-old hamsters. *Ann Fac Med Lima* 2007; 68: 222-237.
24. Lossi L, Tamagno I, Merighi A. Molecular morphology of neuronal apoptosis: analysis of caspase 3 activation during postnatal development of mouse cerebellar cortex. *J Mol Histol* 2004; 35: 621-629.
25. Majewska MD, Urbanowicz E, Rok-Bujko P, Namysłowska I, Mierzejewski P. Age-dependent lower or higher levels of hair mercury in autistic children than in healthy controls. *Acta Neurobiol Exp (Wars)* 2010; 70: 196-208.
26. Matyja E, Taraszewska A, Nagańska E, Grieb P, Rafałowska J. CDP-choline protects motor neurons against apoptotic changes in a model of chronic glutamate excitotoxicity in vitro. *Folia Neuropathol* 2008; 46: 139-148.
27. Merrick J, Kandel I, Morad M. Trends in autism. *Int J Adolesc Med Health* 2004; 16: 75-78.
28. Mossakowski J, Dymecki J, Wender M. *Podstawy neuropatologii*. PZWL, Warszawa 1981; pp: 64-101.
29. Mutter J, Naumann J, Schneider R, Walach H, Haley B. Mercury and autism: accelerating evidence? *Neuro Endocrinol Lett* 2005; 26: 439-446.
30. Nagańska E, Matyja E. Expression of apoptosis-related proteins in model of anoxia in vitro. *Folia Neuropathol* 2005; 43: 23-29.
31. Nagashima K. A review of experimental methylmercury toxicity in rats: neuropathology and evidence for apoptosis. *Toxicol Pathol* 1997; 25: 624-631.
32. Newschaffer CJ, Falb MD, Gurney JG. National autism prevalence trends from United States special education data. *Pediatrics* 2005; 115: e277-282.
33. Olczak M, Duszczyk M, Mierzejewski P, Majewska MD. Neonatal administration of a vaccine preservative, thimerosal, produces lasting impairment of nociception and apparent activation of opioid system in rats. *Brain Res* 2009; 1301: 143-151.
34. Olczak M, Duszczyk M, Mierzejewski P, Majewska MD. Early postnatal Thimerosal administration, in a vaccination-like scheme, causes vast structural damage in rat brain: implications for autism. *Acta Neurobiol Exp (Wars)* 2009; 69: 309.
35. Olczak M, Duszczyk M, Mierzejewski P, Bobrowicz T, Majewska MD. Neonatal administration of thimerosal causes persistent changes in mu opioid receptors in the rat brain. *Neurochem Res* 2010; 35: 1840-1847.
36. Parran DK, Barker A, Ehrlich M. Effects of thimerosal on NGF signal transduction and cell death in neuroblastoma cells. *Toxicol Sci* 2005; 86: 132-140.
37. Paxinos G, Watson C. *The Rat Brain in Stereotaxic Coordinates*. Academic Press, Oxford 2007.
38. Qvarnström J, Lambertsson L, Havarinasab S, Hultman P, Frech W. Determination of methylmercury, ethylmercury, and inorganic mercury in mouse tissues, following administration of thimerosal, by species-specific isotope dilution GC-inductively coupled plasma-MS. *Anal Chem* 2003; 75: 4120-4124.
39. Rice DC. Sensory and cognitive effects of developmental methylmercury exposure in monkeys, and a comparison to effects in rodents. *Neurotoxicology* 1996; 17: 139-154.
40. Rice D, Barone S Jr. Critical periods of vulnerability for the developing nervous system: evidence from humans and animal models. *Environ Health Perspect* 2000; 108 Suppl 3: 511-533.
41. Sajdel-Sulkowska RM, Lipinski B, Windom H, Audhya T, McGinnis W. Oxidative stress in autism: elevated cerebellar 3-nitrotyrosine levels. *American Journal of Biochemistry and Biotechnology* 2008; 4: 73-84.
42. Sakamoto M, Kakita A, de Oliveira RB, Sheng Pan H, Takahashi H. Dose-dependent effects of methylmercury administered during neonatal brain spurt in rats. *Brain Res Dev Brain Res* 2004; 152: 171-176.
43. Seaberg RM, van der Kooy D. Adult rodent neurogenic regions: the ventricular subependyma contains neural stem cells, but

- the dentate gyrus contains restricted progenitors. *J Neurosci* 2002; 22: 1784-1793.
44. Shanker G, Aschner JL, Syversen T, Aschner M. Free radical formation in cerebral cortical astrocytes in culture induced by methylmercury. *Brain Res Mol Brain Res* 2004; 128: 48-57.
  45. Slotkin TA, Bartolome J. Biochemical mechanisms of developmental neurotoxicity of methylmercury. *Neurotoxicology* 1987; 8: 65-84.
  46. Sulejczak D, Grieb P, Walski M, Frontczak-Baniewicz M. Apoptotic death of cortical neurons following surgical brain injury. *Folia Neuropathol* 2008; 46: 213-219.
  47. Takeuchi T. Pathology of Minamata disease. With special reference to its pathogenesis. *Acta Pathol Jpn* 1982; 32 Suppl 1: 73-99.
  48. Vendrell I, Carrascal M, Vilaró MT, Abián J, Rodríguez-Farré E, Suñol C. Cell viability and proteomic analysis in cultured neurons exposed to methylmercury. *Hum Exp Toxicol* 2007; 26: 263-272.
  49. Yel L, Brown LE, Su K, Gollapudi S, Gupta S. Thimerosal induces neuronal cell apoptosis by causing cytochrome c and apoptosis-inducing factor release from mitochondria. *Int J Mol Med* 2005; 16: 971-977.
  50. Yin Z, Milatovic D, Aschner JL, Syversen T, Rocha JB, Souza DO, Sidoryk M, Albrecht J, Aschner M. Methylmercury induces oxidative injury, alterations in permeability and glutamine transport in cultured astrocytes. *Brain Res* 2007; 1131: 1-10.
  51. Young H, Geier D, Geier M. Thimerosal exposure in infants and neurodevelopmental disorders: An assessment of computerized medical records in the Vaccine Safety Datalink. *J Neurol Sci* 2008; 271: 110-118.
  52. Zieminska E, Toczyłowska B, Stafiej A, Lazarewicz JW. Low molecular weight thiols reduce thimerosal neurotoxicity in vitro: Modulation by proteins. *Toxicology* 2010; 276: 154-163.