

## Neuroblastoma and opsoclonus-myoclonus-ataxia syndrome – clinical and pathological characteristics

Joanna Stefanowicz<sup>1</sup>, Ewa Iżycka-Świeszewska<sup>2</sup>, Elżbieta Drożyńska<sup>1</sup>, Jerzy Pienczk<sup>3</sup>, Katarzyna Połczyńska<sup>1</sup>, Piotr Czauderna<sup>4</sup>, Danuta Sierota<sup>1</sup>, Ewa Bień<sup>1</sup>, Teresa Stachowicz-Stencel<sup>1</sup>, Wojciech Kosiak<sup>5</sup>, Anna Balcerska<sup>1</sup>

<sup>1</sup>Department of Paediatrics, Haematology, Oncology and Endocrinology, Medical University of Gdańsk, Poland; <sup>2</sup>Department of Pathomorphology, Medical University of Gdańsk, Poland; <sup>3</sup>Department of Developmental Neurology, Medical University of Gdańsk, Poland; <sup>4</sup>Department of Paediatric Surgery, Medical University of Gdańsk, Poland; <sup>5</sup>Department of Paediatric and Adolescent Nephrology and Hypertension, Medical University of Gdańsk, Poland

*Folia Neuropathol* 2008; 46 (3): 176-185

### Abstract

**Introduction:** Opsoclonus-myoclonus-ataxia (OMA) syndrome is the most common paraneoplastic neurological syndrome in childhood.

**Materials and Methods:** We reviewed the literature and reported on clinical and pathological characteristics of four children with OMA and peripheral neuroblastic tumours. In two of the children the onset of neurological symptoms was connected with a vaccination and in one with viral infection. The suprarenal gland was the primary localization of the tumour in 3 of the children and in one the tumour was located in the retroperitoneal area. All cases were in stage II or III of the disease, with no metastases or MYCN amplification. The group included two ganglioneuroblastomas, one ganglioneuroma and one differentiating neuroblastoma. The tumours were characterized by the presence of lymphocytic infiltrations with lymphadenoplasia. Immunohistochemical analysis of inflammatory infiltrations revealed mixed type populations of lymphocytes with prevalence of the cytotoxic type (CD8 and CD56-positive cells). The participation of dendritic cells and macrophages was also detected. All patients were treated by surgery alone or with adjuvant chemotherapy with a positive outcome. In 3 cases persistent neurological disorders were observed with exacerbations during infections.

**Conclusion:** In some patients the onset of OMA is related to vaccination or infection. Children with OMA and neuroblastoma despite a good oncological prognosis often present permanent neurological and developmental deficits. The inflammatory infiltrations within the tumours are combined, with predominant participation of cytotoxic cells.

**Key words:** peripheral neuroblastic tumours (pNT), opsoclonus-myoclonus-ataxia, pathology, clinical outcome, paraneoplastic syndrome.

### Introduction

Paraneoplastic neurological syndromes are immunologically driven processes. They develop when

tumours expressing onconeural antigens elicit an immune response which destroys the central neurons that normally express these antigens [8,25]. In most patients neurological disorder precedes cancer

### Communicating author:

Joanna Stefanowicz, Klinika Pediatrii, Hematologii, Onkologii i Endokrynologii Dziecięcej, Akademia Medyczna, ul. Dębinki 7, 80-952 Gdańsk, Poland, tel. +48 58 349 28 80, fax +48 58 349 28 63, Email: jstefanowicz@amg.gda.pl

detection. Paraneoplastic syndromes usually progress rapidly and are severely disabling within weeks to months [8,11,13].

Opsoclonus-myoclonus ataxia (OMA) syndrome is the most common paraneoplastic neurological syndrome of childhood. It is an acute neurological disorder characterized by involuntary, chaotic eye movements (which may continue during sleep) and/or by myoclonus and ataxia of the limbs (“dancing feet”), the trunk, and the eyelids [12,16,30]. Opsoclonus and myoclonus are essential features of the disease, but ataxia and other abnormalities are common [16,26]. Other names of the syndrome are: Kinsbourne syndrome, dancing eyes syndrome and myoclonic encephalopathy [12,16,31].

OMA is a rare neurobehavioral paraneoplastic disorder found in less than 4% of patients with neuroblastoma (NB) [10,26]. However, most tumours are occult and may require repeated investigations for their detection [14,30]. The survival rate of neuroblastoma patients with OMA is generally favourable, because the majority of them have localized tumours, belonging to the low-risk group [10,17,26]. It was also shown that those tumours usually have a single copy of the MYCN oncogene [5,20,27].

The pathogenesis of OMA is still unclear, although the presence of anti-neuronal antibodies against unknown membrane antigens of neuroblastoma cells and cerebellar neurons suggests that the disorder is immunologically mediated [1,6,11]. According to some of the reports concerning neuroblastic tumours with OMA available in the literature, their morphological features are diffuse and are characterized by extensive lymphocytic infiltration with the formation of lymphoid follicles [6,10]. These findings suggest that the pathogenesis of OMA might be an autoimmune phenomenon mediated by antibodies cross-reacting with antigens on neuroblasts and on neuronal cells in the cerebellum and the brain stem [7,4,11].

The pharmacological treatment of the neurological disorders includes glucocorticoids, high doses of immunoglobulins, and cytotoxic drugs. 60-80% of patients respond to treatment [3,4,11]. However, the long-term neurological outcome in patients with OMA is variable. The neurological symptoms can persist after removal of the primary tumour [13,17,19]. The neurodevelopmental results of OMA treatment are still poor (60-70% with permanent disabilities) [19,26,31]. Many patients experience developmental delays, including cognitive and motor impairment,

language deficits, and behavioural abnormalities [17,26,27]. Children with persistent symptoms of OMA have the same cognitive delay, language problems, and mood changes as those seen in children who survive posterior fossa tumours and develop chronic cerebellar cognitive affective syndrome [19,29,31].

Our work presents clinicopathological characteristics of four neuroblastoma patients with OMA treated in the Medical University of Gdansk.

## Material and Methods

In the years 1992-2006, among 63 children with peripheral neuroblastic tumours (pNT) treated in the Department of Paediatrics, Haematology, Oncology and Endocrinology of the Medical University of Gdańsk (MUG), 4 children were diagnosed with pNT and OMA. We present detailed patients' clinical and pathological data, including the results of the oncological treatment and actual neurological and developmental status (Tab. I). All patients underwent surgery at the Department of Paediatric Surgery of MUG. All cases were diagnosed pathologically at the Department of Pathomorphology of MUG.

The immunohistochemical analysis of the inflammatory infiltrates within tumours was performed with antibodies against LCA, CD3, CD20, CD56, CD4, CD8, TNF alpha, CD68, HLA-DR, kappa, lambda, CD21, MHC-1 (Dako, Denmark; Novocastra, England) with En Vision method. MYCN status was examined in the Department of Biology and Genetics of MUG using the FISH method from the tumour imprints or tumour sections from the paraffin blocks.

## Clinical study

### Patient 1

A 15-month old girl (S.K.) was admitted to the Paediatric Ward due to an infection of the upper respiratory tract and concomitant anxiety. Two days prior to the onset of symptoms the child had been vaccinated against measles. A few days later she developed rapidly intensifying, generalized myoclonias, ataxia, balance impairments and nystagmus. The child was transferred to the Department of Developmental Neurology of MUG, where she additionally presented intense myoclonias, distinct opsoclonus and hyperexcitability. Kinsbourne syndrome was dia-

**Table I.** Clinical characteristics of patients with OMA and pNT (patient data summary)

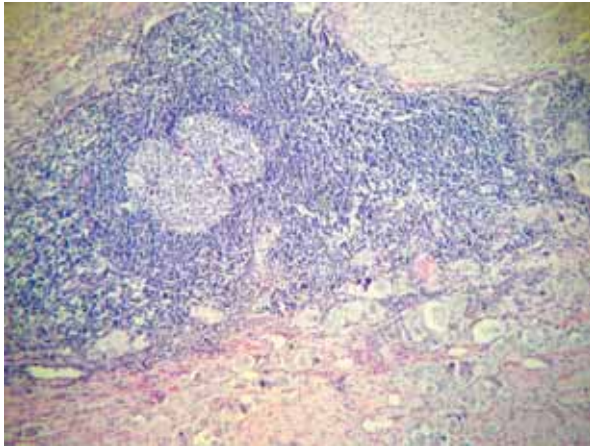
Case/gen-der	Age at onset/diagnosis	Related to vaccination or infection	Primary localization of the tumour/size/ stage	Histological diagnosis	Results of treatment	Neurological and developmental status
1. S.K./F	15mo-90mo	yes – (vaccination against measles)	right suprarenal gland/ (3.8 × 3.2 × 2.8 cm)/I	GN (mature ganglioneuroma)	complete remission of the neoplasm (48 months)	mental retardation of moderate degree – education for handicapped children in a public school; neurological deficits (impaired balance); constantly on steroids
2. M.M./F	16mo-22mo	yes (vaccination against hemophilus influenzae type B)	right retroperitoneal area/ (2.5 × 1.6 × 2.0 cm)/II	GNB inter-mixed (borderline with ganglioneuroma)	complete remission of the neoplasm (36 months)	normal psychomotor development; without neurological deficits
3. M.M./M	48mo-50mo	chickenpox a month before onset	right suprarenal gland/ (5.5 × 3.5 × 2 cm)/III	NB differentiating type Schwannian stroma-poor. Low MKI	complete remission of the neoplasm (24 months)	normal mental development; behaviour disturbances (negativism, irritability); persistent cerebellar syndrome increasing during infections; periodically on steroids
4. L.M./F	40mo-42mo	no	right suprarenal gland 4/4.5 cm/III	GNB inter-mixed Low MKI	complete remission of the neoplasm (180 months)	normal mental development; behaviour disturbances (negativism, irritability); cerebellar syndrome; fine tremor; periodically on steroids

GN – ganglioneuroma; GNB – ganglioneuroblastoma; NB – neuroblastoma.

gnosed. Complex diagnostics for neuroblastoma, including its biochemical markers, as well as imaging examinations including ultrasound and CT of the abdomen and the mediastinum, were carried out, with no pathological findings. The introduced treatment included steroids (hydrocortisone), benzodiazepines and inosine pranobex and after 6 weeks clinical improvement was obtained. The girl was discharged home on steroids (hydrocortisone). However, in the course of some respiratory tract infections an exacerbation of the neurological symptoms, requiring short-term augmentation of the steroid doses, was observed. During control visits a screening abdominal ultrasound and an assessment of the level of catecholamines and their metabolites in the serum were carried out. Six years after the onset of OMA in a control ultrasound a tumour of the right suprarenal gland measuring about 3.5/3 cm was found. The lesion was well delineated, solid, with a low echogenicity and small hyperechogenic reflections. The

adrenal tumour was confirmed by a CT scan. Other diagnostics – bone scintigraphy, bone marrow biopsy and CT scan of the thorax – excluded the presence of metastases. The girl underwent a radical tumour excision. Macroscopically the lesion was oval, encapsulated, composed of yellowish, lobular and shining tissue, measuring 3.8/3.2/2.8 cm.

Histologically a mature ganglioneuroma (neuroblastoma Schwannian stroma-dominant) was diagnosed. No amplification of the MYCN oncogene was found. The tumour was composed of abundant mature Schwannian stroma with ganglion cells forming aggregations or scattered throughout the stroma. Diffuse and extensive lymphocytic infiltrations, with lymphadenoplasia, were present within the tumour. The lymphocytic infiltrates invaded the gangliocyte aggregates with the active destruction of the neural cells, which imitated ganglionitis (Fig. 1). The inflammatory infiltrates also invaded stromal perivascular spaces with focal vascular wall involvement. Small,



**Fig. 1.** Histological picture of tumour – case 1: intense and diffuse lymphocytic infiltrates with lymphoid follicle formation within ganglioneuroma (HE.  $\times 100$ )

scarce calcifications were among the additional findings within the tumour.

At present the girl remains under neurological and psychological control. After the surgery neurological disorders persist with similar intensity. Mental retardation of moderate degree was confirmed. She receives education for disabled children, but attends a public school. Every single infection intensifies the symptoms of OMA. The girl is being constantly treated with hydrocortisone admitted orally.

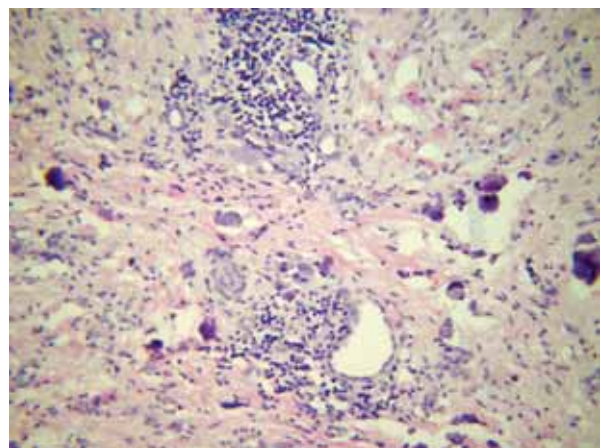
## Patient 2

A 16-month old girl (M.M.) was hospitalized due to nystagmus and impaired balance – at that time she was diagnosed with an allergic neurological reaction caused by a vaccination against *Haemophilus influenzae* type B. Her psychomotor development was adequate for her age. The patient was treated using steroids (prednisone) with significant clinical improvement up to a full regression of neurological symptoms. However, soon after withdrawal of the steroids a recurrence of the neurological symptoms occurred with nystagmus, ataxia and dysmetria of the lower extremities. Two months after the onset of the symptoms she was transferred to the Department of Developmental Neurology. The abdominal ultrasound and an MRI showed the presence of a solid, focal, well circumscribed mass with visible calcifications, measuring 2.5/2.0 cm, in the retroperi-

toneal area. Other diagnostic examinations such as bone scintigraphy, bone marrow biopsy, and CT scan of the thorax excluded the presence of metastases. Subtotal surgical resection of the tumour was achieved, with focally positive section margins.

At the gross examination the tumour measured 3.2/2/2.4 cm and was composed of a creamy-yellow coloured tissue with numerous calcifications. Histologically it was classified as borderline ganglioneuroblastoma/ganglioneuroma maturing subtype (neuroblastoma Schwannian stroma predominant). No MYCN amplification was found. The neoplasm was formed mainly by ganglioneuroma tissue with small areas of differentiating neuroblastoma. Numerous calcifications and lymphocytic infiltrates were dispersed throughout the tumour. Inflammatory changes had mainly perivascular location (Fig. 2). The destruction of maturing ganglioid cells by lymphocytes was also present.

The patient was given chemotherapy consisting of cyclophosphamide, doxorubicin, vincristine, cisplatin, ifosfamide and teniposide over a 10-month period. The chemotherapy was well tolerated. The treatment ended with a complete remission of the neoplastic disease and a total withdrawal of neurological OMA symptoms after 2 months from the start of therapy. Currently, 3 years after the end of treatment, the girl is developing well, without any neurological impairments. The child remains under the care of the Developmental Neurology and the Children's Oncology Outpatient Departments.



**Fig. 2.** Histological picture of tumour – case 2: perivascular lymphocytic cuffs within the tumour with calcifications (HE.  $\times 200$ )



### Patient 3

A 4-year old boy (M.M.) was admitted to the Children's Ward with balance and gait impairments, changes in temper and morning sickness which persisted for a period of 2 months. A month before the onset of the symptoms he suffered from chickenpox. Until that time his psychomotor development was normal. At the time of admission his general state was good, but an unsteady gait, slight ataxia, reduced muscle tone and difficulties with carrying out precise procedures were noticeable. A CT exam of the brain showed no pathological findings. Postinfectious cerebellar ataxia was suggested, but in succeeding days the boy developed generalized muscle hypotonia, balance and gait impairments and opsoclonus. A lumbar puncture revealed no changes in the cerebrospinal fluid. Due to increasing neurological symptoms, and the occurrence of nystagmus and speech articulation disorders, the child was transferred to the Department of Developmental Neurology of MUG with the suspicion of a neurodegenerative process. MRI of the brain and the vertebral column excluded neoplastic and infectious process within the CNS. Kinsbourne's encephalopathy was diagnosed. An abdominal ultrasound and a CT scan showed the presence of a 3.5/3 cm tumour in the right suprarenal gland with numerous calcifications. No metastases or changes in biochemical examinations were diagnosed. Laparoscopic adrenalectomy was performed.

On gross examination the encapsulated tumour 5.5/3.5/2 cm in size was composed of glistening creamy-grey, focally haemorrhagic solid tissue. A histopathological examination revealed neuroblastoma, Schwannian stroma-poor, differentiating type. MYCN was not amplified, MKI was low. The tumour disclosed lobular architecture separated with extensive lymphocytic infiltrations. Lymphocytes from these inflammatory intratumoural septa destructively infiltrated neuroblastic lobules (Fig. 3). Focal formation of lymphoid follicles was also found. What is more, scarce parenchymal calcifications and small haemorrhages were observed. In the periphery of the lesion neoplastic emboli were found focally.

The patient was qualified for chemotherapy appropriate for stage III of the disease according to the SIOP protocol for children above the 1<sup>st</sup> year of age, with unresectable localised neuroblastoma without MYCN amplification [34]. Within 4 weeks of

chemotherapy and steroid (prednisone) treatment a fast withdrawal of neurological symptoms was observed. The therapy ended with a complete remission of the neoplastic disease and total normalization of the neurological status. However, a year after the diagnosis in the course of a viral infection of the upper respiratory tract the symptoms of OMA, manifested by ataxia and balance impairment, occurred once more and long-term (9 months) treatment with steroids (prednisone) was necessary for neurological normalization. Currently, 2.5 years after the end of treatment, the boy is in total remission of the neoplastic disease and remains under neurological and oncological control. At present symptoms of cerebellar syndrome (impaired balance, muscular hypotonia) and behaviour disturbances (negativism, irritability) with low to intermediate intensity can be observed. The child's intellectual development is normal. Neurological symptoms increase during infections, with a need for steroid (prednisone) treatment.

### Patient 4

A 3.5-year old girl (L.M.) was admitted to the Department of Paediatrics, Haematology, Oncology and Endocrinology with rapidly increasing impaired balance, negativism, irritability, opsoclonus and fine tremor. Her psychomotor development was normal. The radiological examination (CT, ultrasonography) revealed a tumour of the right suprarenal gland measuring 4.5/4 cm. The urine catecholamine metabo-

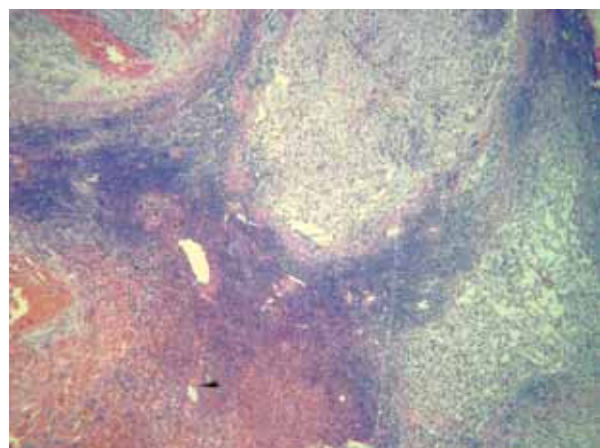


Fig. 3. Histological picture of tumour – case 3: inflammatory infiltrates separating neoplastic lobules (HE. ×20)

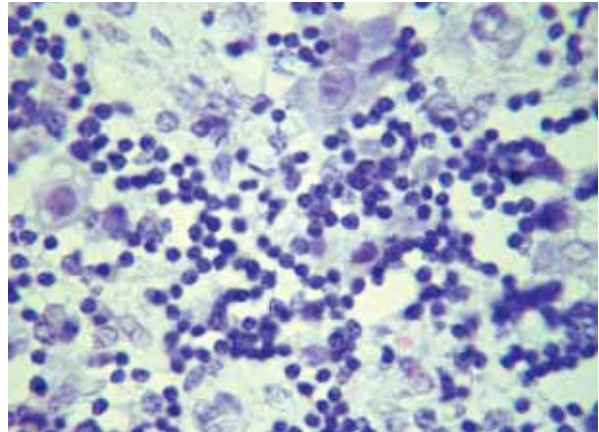
lites were elevated. Non-radical macroscopic surgery of the mass was performed in the Department of Paediatric Surgery.

Macroscopically the tumour was composed of a whitish tissue with involvement of regional lymph nodes. Histologically the neoplasm was consistent with ganglioneuroblastoma intermixed (neuroblastoma Schwannian stroma-rich) with low MKI. The lymphocytic infiltrates within this tumour were dispersed throughout the parenchyma with active destruction of the neuroblastic nodules. Inflammatory cells formed focally perivascular cuffs (Fig. 4).

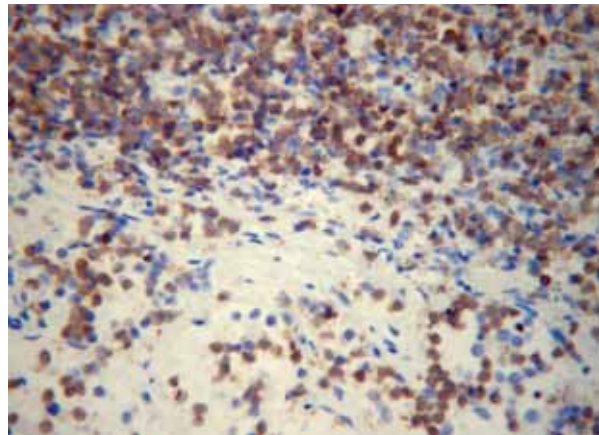
Chemotherapy for stage III neuroblastoma was administered with cyclophosphamide, doxorubicin, vincristine, cisplatin, ifosfamide, etoposide and teniposide. The patient was also treated using steroids (prednisone) with a significant clinical improvement after 4 months of chemotherapy, with only residual behaviour disturbances (negativism, irritability) and fine tremor. The oncological treatment ended with a complete remission of the neoplastic disease. We observed, however, periodic exacerbations of neurologic symptoms, which did not react sufficiently to steroids (prednisone). After 6 years of follow-up the patient was withdrawn from detailed observation due to a change of place of living. From medical correspondence it is known that she is free of cancer, but presents slight symptoms of cerebellar syndrome manifested mainly by impaired balance and behaviour disturbances.

### Immunohistochemical analysis of the inflammatory infiltrates within the tumours

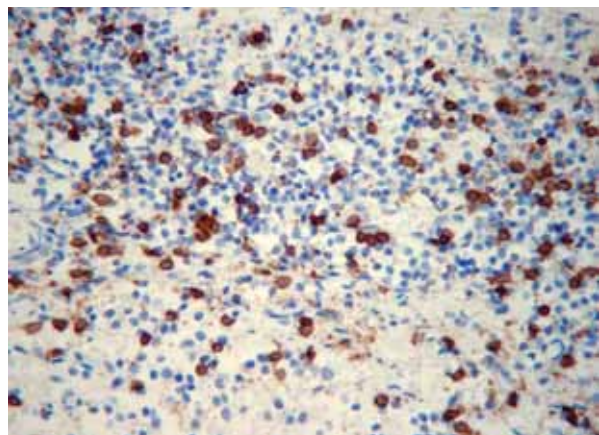
Inflammatory intratumoural infiltrates (LCA-positive) were diffuse (cases 1,2,3,4) or formed lymphoid follicles (cases 1,3). Perivascular concentrations and lymphoid cuffs were also encountered (cases 1,2,3,4). Diffuse infiltrates were composed mainly of T cells (CD3-positive) (Fig. 5A) together with a smaller population of CD56+ cells and less abundant B cells (CD20-positive) (Fig. 5B-C), CD21-positive dendritic cells as well as macrophages (CD68+). Diffuse T cell infiltrations contained predominantly CD8+ cells with few CD4+ lymphocytes. T cell infiltrates and CD56+ cells actively invaded and were destroying neuroblastic and gangliocytic cells (Fig. 5D-E). In the areas of lymphoid follicles formation typically CD20+ cells forming follicular germinal centres and CD3+ cells forming their outer mantle zone were found. HLA-DR expression



**Fig. 4.** Histological picture of tumour – case 4: lymphocytes destroying differentiating neuroblasts (HE,  $\times 400$ )

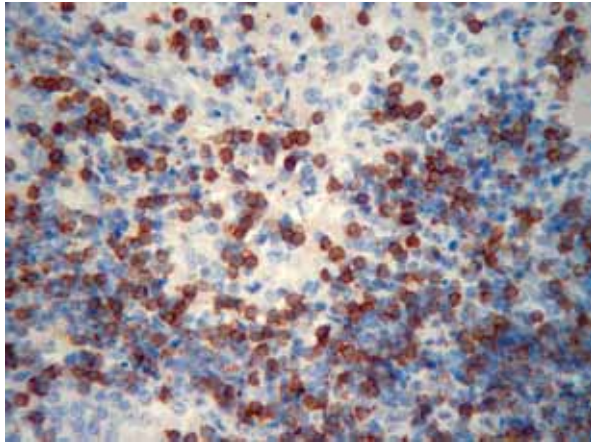


**Fig. 5A.** Inflammatory infiltrates within the neoplastic tissue with predominant population of lymphocytes T (CD3,  $\times 200$ )

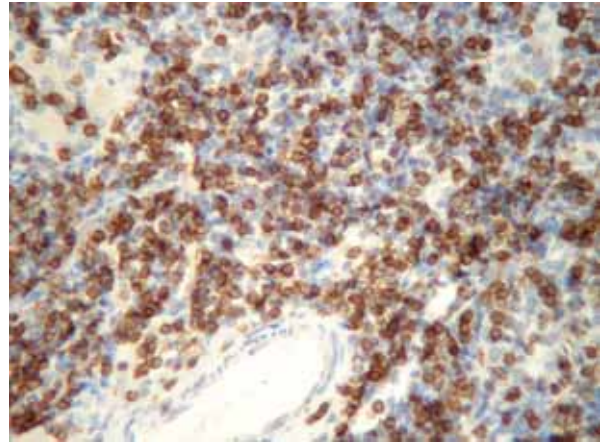


**Fig. 5B.** Disseminated lymphocytes B within the inflammatory cells (CD20,  $\times 200$ )

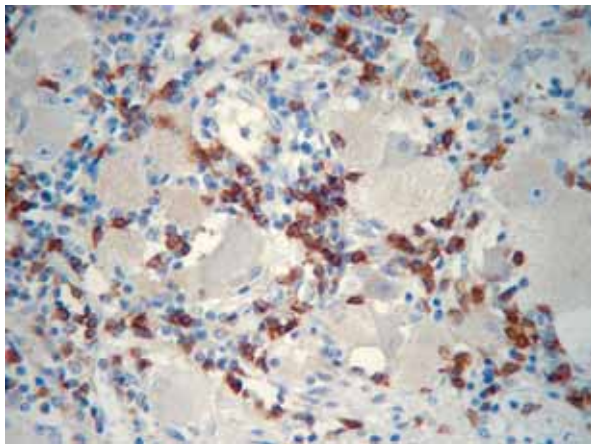




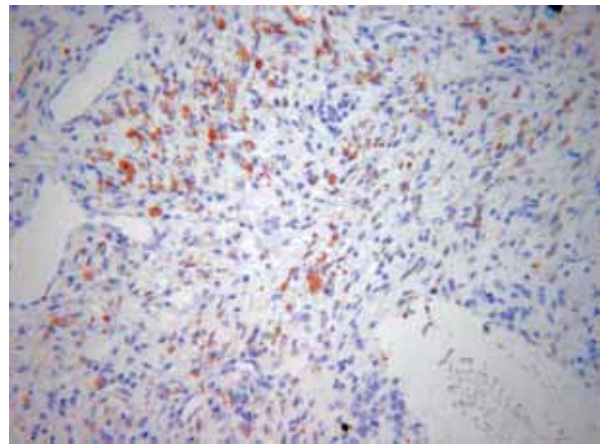
**Fig. 5C.** Multiple CD56-positive NK cells within the lymphocytic infiltrates (CD56,  $\times 200$ )



**Fig. 5D.** Dense infiltrates with cytotoxic CD8-positive cells (CD8,  $\times 200$ )



**Fig. 5E.** CD8- positive lymphocytes surrounding and destroying neurons (CD8,  $\times 200$ )



**Fig. 5F.** TNF alpha expression within the elements of Schwannian stroma (TNF alpha,  $\times 100$ )

was encountered within the germinal centres. The neuroblastic and ganglion cells expressed MHC-1 but did not express HLA-DR antigen. Perivascular infiltrations were made of mixed populations of lymphocytes T and B. TNF alpha labelling was found in scattered cells in the neoplastic Schwannian stroma in macrophages and focally in the endothelial cells (Fig. 5F). Immunolabelling for both kappa and lambda chains was present within some inflammatory cells.

## Discussion

Paraneoplastic neurological syndromes are rare but important in clinical practice. These syndromes are examples of naturally occurring tumour immu-

nity. Tumours causing paraneoplastic neurological syndromes express onconeural antigens which activate an immune response that sometimes successfully suppresses tumour growth [8,11,13,25]. Some of them are associated with presence of onconeural antibodies in serum and cerebrospinal fluid [2,25]. OMA is a rare neurological condition with an acute onset of myoclonus, opsoclonus, and ataxia [16,30]. This syndrome develops very rarely in adult patients with breast cancer in association with Ri antibodies and patients with small cell lung cancer without any characteristic antibodies [11]. In children this rare syndrome is typical for neuroblastoma and was first described by Kinsbourne in 1962 [16]. The first neurological symptoms of OMA usually appear between

18 and 24 months of age, but this disease can affect children of all ages [17,21]. Children with OMA do not improve spontaneously and in order to improve their neurological status treatment with steroids or immunosuppressive or cytotoxic drugs is required [3,4,11].

OMA syndrome very rarely can also develop in association with viral infections or vaccination or without any noticeable reason [17,21]. In idiopathic cases it is assumed that the syndrome could have developed in the course of neuroblastoma which had undergone a complete spontaneous regression [3,21]. In most OMA cases the tumour is of a small size, without any clinical symptoms related to its primary location. Therefore at times repeated imaging examinations must be carried out [5,20,31].

Neurological symptoms of OMA syndrome need to be differentiated from encephalitis, brain tumour, acute cerebellar ataxia and toxic injury [14,19,30]. In contrast to OMA, acute post-infectious cerebellar ataxia is never accompanied by either myoclonia or opsoclonus and rarely by irritability [17]. The clinical course of OMA is related to the prodromal phase manifested by changes in the child's behaviour: extreme irritability, inconsolability and insomnia [17,30]. The symptoms of the disease augment within just a few days. Throughout the acute neurological phase the child suffers from coordination disturbances and frequent falls, accompanied by a decline in neurological status, the loss of ability to sit and stand, fits of anger, blurred speech, hypotonia, tilting of the head, Horner's syndrome, deep tendon reflex disorders or seizures [17,20,30]. The course of the disease has periods of exacerbations and remissions, but it is not progressive [12,26,27]. In Klein's study, concerning ten patients, remission was achieved within a period of 5 months in seven patients and relapses were present in seven [17]. Regarding the long-term outcome, persistent and disabling ataxia, speech abnormalities, behavioural problems and learning disabilities have been described as the main clinical problems [12,19,26]. In some of these patients an MRI examination revealed bilateral cerebellar atrophy [12]. Complete recovery in OMA was seen in only 12-38% of the children [20,26,27].

Neuroblastic tumours in patients with OMA are less aggressive, have a tendency to involute spontaneously or mature, and are associated with a good prognosis [5,6,10,20]. In 90% of neuroblastomas no metastases are found and the results of oncological treatment are usually very good [17,18,31].

Neuroblastic tumour with OMA is usually a ganglioneuroblastoma or differentiating neuroblastoma, characterized histologically by the presence of diffuse, intense lymphocytic infiltrations and lymphatic lumps [6,10,14]. These tumours are usually in the low-risk group according to Shimada and INPC criteria – neuroblastoma with maturation, low MKI, aneuploid, with no MYCN oncogene amplification [5,10,20]. In the inflammatory intratumoural infiltrates T-cell lymphocytes predominate [6,10,28]. The presence of lymphocytic follicles in the tumour tissues suggests that B lymphocytes play a role in the production of combined antibodies directed at both neuroblastoma cells and neurons in the CNS [6,10]. Tumour differentiation as well as apoptosis may possibly be caused by chemokines released by stromal cells due to an inflammatory reaction [6,10]. Neuroblastic cells can present surface antigens – GD2, NCAM, MAG, BAGE, GAGE. However, neither specific or common autoantigens, nor specific antibodies against these antigens were detected in NB patients [1,25]. Blaes et al. showed that the majority of the children with OMA have autoantibodies which bind to the surface of isolated rat cerebellar granular neurons [4]. These antibodies inhibited the proliferation of NB-cells in vitro, and were able to induce apoptosis in NB cells, suggesting a humoral autoimmune pathogenesis of the process [4]. The autoantibodies in OMA, both intracellular and surface binding, belong mainly to the IgG3 subclass [2]. In some NB patients antibodies of type Ri-Ab (ANNA2-Ab) and Hu-Ab (ANNA I-Ab) were detected [13]. However, the contribution of antineuronal antibodies to the pathogenesis of distant neurobehavioural disorders in children with neuroblastoma and OMA is controversial. Some reports showed no antineuronal antibodies in the patients' serum, and no correlations between the late outcome and the titre of these antibodies [12,26].

The patients described in our study presented a classical, clinically full-symptomatic OMA syndrome with its typical acute neurological phase. The age of our four patients at the time of diagnosis of the pNTs was 21, 40, 48 and 90 months respectively. The tumours were in stage II and III, without metastases. In 3 of the children the suprarenal gland was the primary localization of the tumour and in one the retroperitoneal area. None of the tumours showed MYCN amplification. In each of the children opsoclonus and myoclonias occurred parallel to ataxia and balance impairment. In one of the children speech



articulation disorders were additionally observed. None of the children presented symptoms related to the primary localization of the tumour, and OMA was the only symptom of the neoplastic disease. The symptoms of OMA preceded the tumour diagnosis by 2 months, 6 months and 6 years. An important observation in our group was the fact that in two of the children the onset of OMA was primarily connected with a vaccination, while in one of the patients it was associated with a recent history of chickenpox. This is yet further proof of the immunological pathogenesis of OMA. At present all patients are alive with no evidence of neoplastic disease after 2 to 17 years since the end of oncological treatment. One of the children has been diagnosed with mental retardation of moderate degree; in that patient speech articulation disorders were additionally observed. In three patients neurobehavioral deficiencies and conduct disorders are observed. Only one child has normal psychomotor development without any neurological deficits. Another interesting observation is that during a respiratory tract infection two of the patients presented symptoms of full OMA and one isolated balance impairment.

Immunohistochemically we found that CD8 cytotoxic lymphocytes and CD56- positive NK cells were the predominant inflammatory cells infiltrating and destroying neuroblastic and ganglioid cells. This supports the results of the Gambini and Cooper group pointing to the prominent cellular immune response within the tumour [6,10]. On the other hand CD8 cells are the basic population in inflammatory infiltrates of paraneoplastic encephalomyelitis [9,11,15]. We also found CD21+ dendritic cells within the inflammatory infiltrates. Darnell et al. showed that dying tumour cells during cross presentation transfer onconeural antigens to dendritic cells and activate an antigen-specific immune response [8]. Our new observation is the expression of MHC class I molecules on neurons in pNT, possibly induced by cytokine signals, which allows for CD8+ T cells to recognize these cells as targets. We also noticed the perivascular location of lymphocytic cells, which was previously described by the Cooper and Gambini groups [6,10]. Perivascular cuffs can be directly connected with the release of antibodies and cytokines into the blood. Pranzatelli described a previously changed CD4/CD8 ratio in the peripheral blood, as well as consecutive changes in lymphocytic profile in CSF in OMA patients [23]. We also found the presence of TNF alpha in the stromal

macrophages and endothelial cells within examined tumours, which can influence vascular permeability and the inflammatory process [9,28].

We have no knowledge about the pathological changes within the brains of our group of children with OMA. Autopsy-based studies on paraneoplastic neurological syndromes revealed that the main components of cerebellopathy are neuronal loss of Purkinje and granular cells. What is more, demyelination and lymphocytic infiltrates were described [7,9,11,15]. During the rapid onset of the syndrome, activated T-cells are capable of crossing the blood-brain barrier, whence they enter the brain and attack neurons [8,11,13]. Pranzatelli found that in the acute phase of OMA a cell-mediated immunological response dominated [22,23]. Moreover, increased protein levels in CSF of OMA patients are caused by the intrathecal synthesis of antibodies [21,22]. In paraneoplastic encephalopathy Dziewulska et al. found increased PECAM-1 expression in blood vessels [9]. PECAM-1 facilitates transendothelial lymphocytic migration [9]. In chronic phases a beneficial fragile immunological balance causes inactivation of the central process; however, it can be destroyed by viral infections. This may explain the periodic recurrence of symptoms in our three patients, since the viral antigens may provoke similar presentation of antigens as onconeural antigens [8,25].

Based on the analysis of our patients we must emphasise the fact that in some patients the onset of OMA is related to vaccination or infection. The immunohistochemical analysis of the inflammatory infiltrations within the tumours shows mixed type reaction, but of a predominantly cytotoxic type. This intratumoural immunological reaction triggers the paraneoplastic process against the central nervous tissue components. Children with OMA and neuroblastoma often present permanent neurological and developmental deficits despite a good oncological prognosis, and are in need of specialist medical care, rehabilitation, and psychological and social care.

## References

1. Bataller L, Rosenfeld MR, Graus F, Vilchez JJ, Cheung NK, Dalmau J. Autoantigen diversity in the opsoclonus-myoclonus syndrome. *Ann Neurol* 2003; 53: 347-353.
2. Beck S, Fuhlhuber V, Krasenbrink I, Tschernatsch M, Kneifel N, Kirsten A, Jaeger C, Kaps M, Preissner KT, Lang B, Rostasy K, Blaes F. IgG subclass distribution of autoantibodies in pediatric opsoclonus-myoclonus syndrome. *J Neuroimmunol* 2007; 185: 145-149.

3. Blaes F. Immunotherapeutic approaches to paraneoplastic neurological disorders. *Exp Opin Biol Ther* 2002; 2: 419-430.
4. Blaes F, Fuhlhuber V, Korfei M, Tschernatsch M, Behnisch W, Rostasy K, Hero B, Kaps M, Preissner KT. Surface-binding auto-antibodies to cerebellar neurons in opsoclonus syndrome. *Ann Neurol* 2005; 58: 313-317.
5. Cohn SL, Salven H, Herst CV, Maurer HS, Nieder ML, Morgan ER, Rosen ST. Single copies of the N-myc oncogene in neuroblastomas from children presenting with the syndrome of opsoclonus-myoclonus. *Cancer* 1988; 62: 723-726.
6. Cooper R, Khakoo Y, Matthay KK, Lukens JN, Seeger RC, Stram DO, Gerbing RB, Nakagawa A, Shimada H. Opsoclonus-myoclonus-ataxia syndrome in neuroblastoma: histopathologic features – a report from the Children’s Cancer Group. *Med Pediatr Oncol* 2001; 36: 623-629.
7. Dambaska M, Laure-Kamionowska M. Brain damage in children in course of neoplastic diseases. *Folia Neuropathol* 1999; 37: 133-137.
8. Darnell RB. Paraneoplastic neurologic disorders. *Arch Neurol* 2004; 61: 30-32.
9. Dziewulska D, Drac H, Michej W, Mieszkowski J, Rafałowska J. Paraneoplastic syndrome in the course of lung adenocarcinoma: morphological picture and immunohistochemical analysis of the inflammatory infiltrates and PECAM-1 expression. *Folia Neuropathol* 2000; 38: 29-33.
10. Gambini C, Conte M, Bernini G, Angelini P, Pession A, Paolucci P, Donfrancesco A, Veneselli, Mazzocco K, Tonini G, Raffaghello L, Dominici C, Morando A, Negri F, Favre A, De Bernardi B, Pistoia V. Neuroblastic tumors associated with opsoclonus syndrome: histological, immunohistochemical and molecular features of 15 Italian cases. *Virchows Arch* 2003; 442: 555-562.
11. Graus F, Dalmau J. Paraneoplastic neurological syndromes: diagnosis and treatment. *Curr Opin Neurol* 2007; 20: 732-737.
12. Hayward K, Jeremy RJ, Jenkins S, Barkowich AJ, Gultekin SH, Kramer J, Crittenden M, Matthay K. Long-term neurobehavioral outcomes in children with neuroblastoma and opsoclonus-myoclonus-ataxia syndrome: relationship to MRI findings and anti-neuronal antibodies. *J Pediatr* 2001; 139: 552-559.
13. Honnorat J, Antoine J-C. Paraneoplastic neurological syndromes. *Orphanet J Rare Dis* 2007; 2: 22.
14. Izycka-Swieszewska E, Stefanowicz J, Adamkiewicz-Drozyńska E, Pienczk J, Rzepko R. Kinsbourne’s encephalopathy six years before the diagnosis of adrenal ganglioneuroma. *Aktualn Neurol* 2005; 2: 152-156.
15. Kaluza J, Slowinski J, Bujny T, Grochala M. Paraneoplastic syndrome simulating encephalitis in the course of testicular seminoma. *Folia Neuropathol* 1997; 35: 24-28.
16. Kinsbourne M. Myoclonic encephalopathy of infants. *J Neurol Neurosurg Psych* 1962; 25: 271-279.
17. Klein A, Schmitt B, Boltshauser E. Long-term outcome of ten children with opsoclonus-myoclonus syndrome. *Eur J Pediatr* 2007; 166: 359-363.
18. Kushner B, Cohn S, Matthay K. Treatment of Neuroblastoma. In: Cheung N-K, Cohn S (eds.). *Neuroblastoma*. Springer-Verlag, Berlin Heidelberg 2005; pp. 123-131.
19. Levisohn L, Cronin-Golomb A, Schmahmann JD. Neuropsychological consequences of cerebellar tumour resection in children: cerebellar cognitive affective syndrome in a paediatric population. *Brain* 2000; 123: 1041-1050.
20. Plantaz D, Michon J, Valteau-Couanet D, Coze C, Chastagner P, Bergeron C, Nelken B, Martelli H, Peyroulet MC, Carpentier AF, Armari-Alla C, Pagnier A, Rubie H. Opsoclonus-myoclonus syndrome associated with non-metastatic neuroblastoma Long-term survival. Study of the French Society of Pediatric Oncologists. *Arch Pediatr* 2000; 7: 621-628.
21. Pranzatelli MR. The neurobiology of opsoclonus-myoclonus. *Clin Neuropharmacol* 1992; 15: 186-228.
22. Pranzatelli MR, Hyland K, Tate ED, Arnold LA, Allison TJ, Soori GS (2004) Evidence of cellular immune activation in children with opsoclonus-myoclonus: cerebrospinal fluid neopterin. *J Child Neurol* 2004; 19: 919-924.
23. Pranzatelli MR, Travelstead AL, Tate ED, Allison TJ, Lee ND, Fisher J, Jasty R. Immunophenotype of blood lymphocytes in neuroblastoma-associated opsoclonus-myoclonus. *J Pediatr Hematol Oncol* 2004; 26: 718-723.
24. Ramos S, Temudo T. Opsoclonus myoclonus syndrome: how long are we going to go on researching? *Rev Neurol* 2002; 35: 322-325.
25. Roberts W, Darnell RB. Neuroimmunology of the paraneoplastic neurological degenerations. *Curr Opin Immunol* 2004; 16: 616-622.
26. Rudnick E, Khakoo Y, Antunes NL, Seeger RC, Brodeur GM, Shimada H, Gerbing RB, Stram DO, Matthay KK. Opsoclonus-myoclonus-ataxia syndrome in neuroblastoma: clinical outcome and antineuronal antibodies-a report from the Children’s Cancer Group Study. *Med Pediatr Oncol* 2001; 36: 612-622.
27. Russo C, Cohn SL, Petruzzi MJ, de Alarcon PA. Long-term neurologic outcome in children with opsoclonus-myoclonus associated with neuroblastoma: a report from the Pediatric Oncology Group. *Med Pediatr Oncol* 1997; 28: 284-288.
28. Shimada H, Ambros I. Pathology of peripheral neuroblastic tumors. In: Cheung N-K, Cohn S (eds.). *Neuroblastoma*. Springer-Verlag, Berlin Heidelberg 2005; pp. 87-95.
29. SIOP Protocol. Treatment of children over the age of 1 year with unresectable localised neuroblastoma without MYCN amplification. 2000.
30. Tate ED, Allison TJ, Pranzatelli MR, Verhulst SJ. Neuroepidemiological trends in 105 US cases of pediatric opsoclonus-myoclonus syndrome. *J Pediatr Oncol Nurs* 2005; 22: 8-19.
31. Telander RL, Smihson WA, Groover R. Clinical outcome in children with acute cerebellar ecephalopathy and neuroblastoma. *J Pediatr Surg* 1989; 24: 11-14.