

Lung parenchymal involvement and sputum bacteriology in tuberculous pleurisy: correlation with pleural fluid biochemical parameters

Ergun Ucar¹, Ergun Tozkoparan¹, Seyfettin Gumus¹, Omer Deniz¹, Fatih Ors², Ugur Bozlar², Faruk Ciftci³

¹Department of Pulmonary Medicine, Gulhane Military Medical Academy, Ankara, Turkey

²Department of Diagnostic Radiology, Gulhane Military Medical Academy, Ankara, Turkey

³Department of Pulmonary Medicine, Haydarpasa Training Hospital, Gulhane Military Medical Academy, Istanbul, Turkey

Submitted: 28 November 2008

Accepted: 15 March 2009

Arch Med Sci 2009; 5, 3: 450-455

Copyright © 2009 Termedia & Banach

Corresponding author:

Ergun Tozkoparan

GATA Gogus Hastaliklari AD

Etlik 06018 Ankara, Turkey

Fax: + 90 312 304 20 10

Phone: + 90 532 558 99 67

E-mail: etozkoparan@gata.edu.tr,

dretozkoparan@yahoo.com

Abstract

Introduction: It has been shown in some studies that a significant proportion of the cases with tuberculous pleurisy may have positive sputum culture for *Mycobacterium tuberculosis* or associated parenchymal involvement in computed tomography. We aimed to investigate high-resolution computed tomographic (HRCT) findings of lung parenchyma and their correlations with sputum bacteriology, serum and pleural fluid biochemical parameters.

Material and methods: A number of thirty-four patients with tuberculous pleurisy were investigated by using HRCT in order to assess the parenchymal involvement giving a profusion score. The sputum culture for *M. tuberculosis* was also performed. Pleural fluid and adenosine deaminase, (p-ADA) lactate dehydrogenase (p-LDH), protein and albumin levels were quantified and size of the pleural effusion was scored on chest X-ray.

Results: Six of 34 (17.6%) patients had positive sputum culture for *M. tuberculosis*. A significant correlation between HRCT score and p-ADA ($r_s = 0.634$, $p < 0.001$), p-LDH ($r_s = 0.548$, $p = 0.001$) levels and size of the pleural effusion ($r_s = 0.414$, $p = 0.015$) was found. Furthermore, patients with positive *M. tuberculosis* culture in sputum had significantly elevated p-LDH (1790.7 ± 899.4 vs. 955.7 ± 383.2 U/l, $p = 0.002$) and p-ADA (101.8 ± 29.8 vs. 67.8 ± 17.6 U/l, $p = 0.002$), larger pleural effusion and HRCT score ($p = 0.042$ and $p < 0.001$ respectively).

Conclusions: We concluded that degree of inflammation in TP might be affected by simultaneous pulmonary parenchymal changes and sputum bacteriology. It might be suggested that TP might be a different manifestation of pulmonary TB rather than an extra-pulmonary disease.

Key words: pleural fluid biochemistry, pulmonary involvement, tuberculous pleurisy.

Introduction

It seems that tuberculosis (TB) will have continued to be an important public health problem after several decades in many developing countries and developed ones as well. The incidence of extrapulmonary tuberculosis has been increasing mainly due to its close association with human immunodeficiency virus infection and some atypical presentations constitutes diagnostic dilemma for clinicians [1]. Tuberculous pleurisy (TP) is the second leading manifestation of extrapulmonary TB [2] and it constitutes two major problems in daily medical practice. One is that

diagnosis of TP can be difficult as is in other extrapulmonary TB forms. Laboratory investigations including pleural fluid chemistry and microbiology in conjunction with even culture and histological analysis of pleural biopsy samples may remain non-diagnostic in 10-20% of cases with TP. Although it is an infectious disease, various biochemical markers and cytokines have been investigated in order to make a rapid diagnosis of TB and TP [3-5]. Secondly, although it is primarily considered as an extrapulmonary disease, recent studies have shown that the cases with TP in a significant proportion have pulmonary involvement simultaneously demonstrated by sputum culture for *Mycobacterium tuberculosis* (*M.tb.*) or computed tomographic (CT) images [6-9].

With these considerations in mind, we have evaluated high resolution computed tomographic (HRCT) findings of lung parenchyma and their correlations with sputum bacteriology, serum and pleural fluid chemistry in order to reveal relation and importance of parenchymal pulmonary involvement in TP.

Material and methods

Patients

This study was conducted at Department of Pulmonary Medicine of Gulhane Military Medical Academy. It is a teaching hospital that serves as the biggest referral center for Turkish Armed Forces and it is a primary care facility in Ankara metropolitan area. From January 2005 to December 2005, all consecutive patients with TP were evaluated prospectively. Patients with associated pulmonary and extra-pulmonary diseases were excluded. Finally, 34 patients with TP were included into the study. Diagnosis of TP was confirmed with either necrotizing caseous granulomatous inflammation in closed pleural biopsy specimens or isolation of *M.tb.* from pleural fluid or biopsy samples. Patients were not tested for human immunodeficiency virus (HIV) infection, as it is not routinely recommended in Turkey due to the very low prevalence. The local ethical committee of the academy approved the study and an informed consent was obtained from each patient.

Measurement of pleural fluid and serum biochemical parameters

Thoracentesis to obtain pleural fluid and simultaneous venous puncture were performed in 48 h after the admission of each patient before starting antituberculous treatment. Biochemical parameters including adenosine deaminase (ADA), lactate dehydrogenase (LDH), protein and albumin in serum and pleural fluid samples were determined at the central laboratory of Gulhane Military Medical Academy. Total protein, albumin and LDH levels

were measured with a spectrophotometric technique by Olympus AU-2700 autoanalyzer and using commercial kits (Olympus, Hamburg, Germany). ADA levels were determined by Giusti's colorimetric method as previously described [10]. Complete blood count and erythrocyte sedimentation rate (ESR) were also determined.

Microbiological investigations

Three sputum samples collected in consecutive days from the patients who were able to expectorate spontaneously, otherwise induced sputum was obtained. Pleural fluid samples were also investigated for mycobacterial culture for each patient. Standard smears were for acid-fast bacilli (AFB) prepared by Ziehl-Neelson staining and mycobacterial cultures were performed both on Lowenstein-Jensen media and radiometric BACTEC TB 460 system with a total incubation period of 8 weeks.

Radiological imaging

High-resolution computed tomographics were performed at 10 mm section interval (120 kV, 175 mA, 1 mm slice thickness, 1.5 s scanning time) with a window level between -650 and -800 Hounsfield Units (HU) and window width between 1400 and 1600 HU using the GE Medical System HiSpeed CT/i (Milwaukee, USA). Parenchymal changes attributable to TB seen on HRCT were scored as previously described [11, 12]. In brief, the presence, distribution, and extent of the following signs were evaluated:

- 1) micronodule (MN) (nodules: 1 to 3 mm);
- 2) nodule (nodules: 4 to 10 mm);
- 3) consolidation (panlobular and polylobular opacities bigger than 10 mm);
- 4) ground glass opacity (GGO);
- 5) cavity;
- 6) bronchial lesion (bronchial wall thickening, bronchiectasis);
- 7) parenchymal bands.

On the HRCT scans, each lung were divided into three zones which are defined as the "upper zone" above the level of the carina; the "middle zone" between the level of the carina and the level of the inferior pulmonary veins; and the "lower zone" below the level of the inferior pulmonary veins. The HRCT score was determined by visually estimating the extent of disease in each zone. The score was based on the percentage of lung parenchyma that showed evidence of each recorded abnormality:

- 1) involvement of less than 25% of the image;
- 2) 25 to 50%;
- 3) 50 to 75%;
- 4) more than 75%.

A profusion score of each lesion (0-4) was given and the scores of each zone were then summed to

obtain a global profusion score for HRCT ranging from 0 to 24 for two lungs theoretically. A total HRCT score was generated by adding the partial scores of all 7 parameters. Altogether, the total score for two lungs ranged between 0 and 168.

For assessment of size of the pleural effusion, we used an effusion scoring system previously defined by Han *et al.* as follows : 1 = costophrenic angle obscured; 2 = entire diaphragm obscured; 3 = entire diaphragm obscured, but fluid level below the hilum; 4 = up to the hilum; and 5 = above the hilum [13].

In all patients, HRCT scans and chest X-rays were interpreted by two radiologists who were aware of the diagnosis of TP but blinded to all biochemical and microbiological findings.

Table I. Demographic features, HRCT findings, pleural fluid biochemical parameters and mycobacterial culture results of 34 patients with TP

Parameter	Value
Mean age [years]	22.6 ±2.9
Male/female	32/2
HRCT scores of the signs:	
Cavity	0.1 ±0.7
MN	0.8 ±1.7
Nodule	2.8 ±2.1
Consolidation	3.4 ±1.7
Ground glass opacity	3.7 ±1.6
Bronchial lesion	0.6 ±0.9
Parenchymal band	4.1 ±1.3
Total HRCT score	15.6 ±7.3
Effusion score (chest X-ray)	2.8 ±0.9
Biochemical parameters:	
ESR [mm/h]	44.7 ±21.7
p-LDH [U/l]	1103.1 ±589.1
p-total protein [g/dl]	5.11 ±0.45
p-albumin [g/dl]	3.07 ±0.34
p-ADA [U/l]	73.8 ±23.7
s-LDH [U/l]	414.8 ±78.1
s-total protein [g/dl]	6.79 ±0.69
s-albumin [g/dl]	4.16 ±0.5
s-ADA [U/l]	28.3 ±8.8
Positive mycobacterial culture:	
Sputum	6 (17.6%) [2-12]*
Pleural fluid	5 (14.7%) [2-11]*

*In parenthesis (percentage) and in brackets (95% confidence intervals of the cases).

Statistical analysis

Descriptive statistics were shown as mean ± standard deviation. Correlations between the radiological scores and biochemical parameters were calculated by means of the Spearman's correlation test and correlation coefficient was symbolized by " r_s ". The absolute r_s values between 0.25-0.50, 0.50-0.75 and 0.75-1.0 with a p value greater than 0.05 were accepted as weak, moderate and strong correlations respectively. The differences of biochemical parameters and radiological scores between the subgroups of positive and negative culture result for *M.Tb.* in pleural fluid and sputum samples were compared by using the Mann-Whitney U test. Fisher Exact Test was performed to compare the proportion of the positive results for *M.tb.* culture in these subgroups (i.e. pleural fluid culture positivity rate in patients with positive sputum culture and sputum culture positivity rate in those with positive pleural fluid culture result). A p value lower than 0.05 was considered as significant.

Results

Patients' clinical, laboratory and radiological characteristics were shown in Table I. All of the patients had parenchymal lung lesions on HRCT scans which were all located on effusion side. The HRCT scores of pulmonary parenchymal alterations in patients with TP showed significant positive correlations with pleural fluid LDH (p-LDH), ADA (p-ADA), serum LDH (s-LDH), ADA (s-ADA) and effusion score (r_s values are 0.548, 0.634, 0.431, 0.41, 0.414 and p values are 0.001, <0.0001, 0.011, 0.016 respectively) while it correlated negatively with serum albumin ($r_s = -0.594$) (Figure 1). There was no significant correlation between HRCT score and pleural fluid protein (p-protein), and albumin (p-albumin) levels. When the study population was sub-grouped with respect to sputum culture results, the patients with a positive sputum culture were differed from those with a negative result in terms of p-LDH, p-ADA, serum albumin, effusion and HRCT score pleural fluid mycobacterial culture positivity (Table II). Only HRCT score, however, differed significantly in patients with a positive result for pleural fluid mycobacterial culture with respect to those with a negative result.

Discussion

We have demonstrated that all of the 34 patients with TP had pulmonary parenchymal changes on HRCT scans. The extent of the lung involvement correlated significantly with p-ADA and p-LDH and size of the pleural effusion. Furthermore sputum *M.Tb.* positivity resulted in higher p-ADA and p-LDH levels and more *M.Tb.* growth in PF. These results indicate that pulmonary parenchymal involvement

may have some effect on disease extent and severity in TP.

Although demonstration of pulmonary parenchymal involvement in TP is not very surprising, little data about this subject have been published in the current literature. Yilmaz *et al.* reported that underlying lung parenchymal abnormalities were seen in 39% of the patients with TP whereas those were shown in all of 24 cases with TP in another study [6, 9]. Similarly, Kim *et al.* demonstrated that lung parenchymal lesion on chest CT in 86% of the patients with TP [8]. High-resolution computed tomographic is currently the most accurate

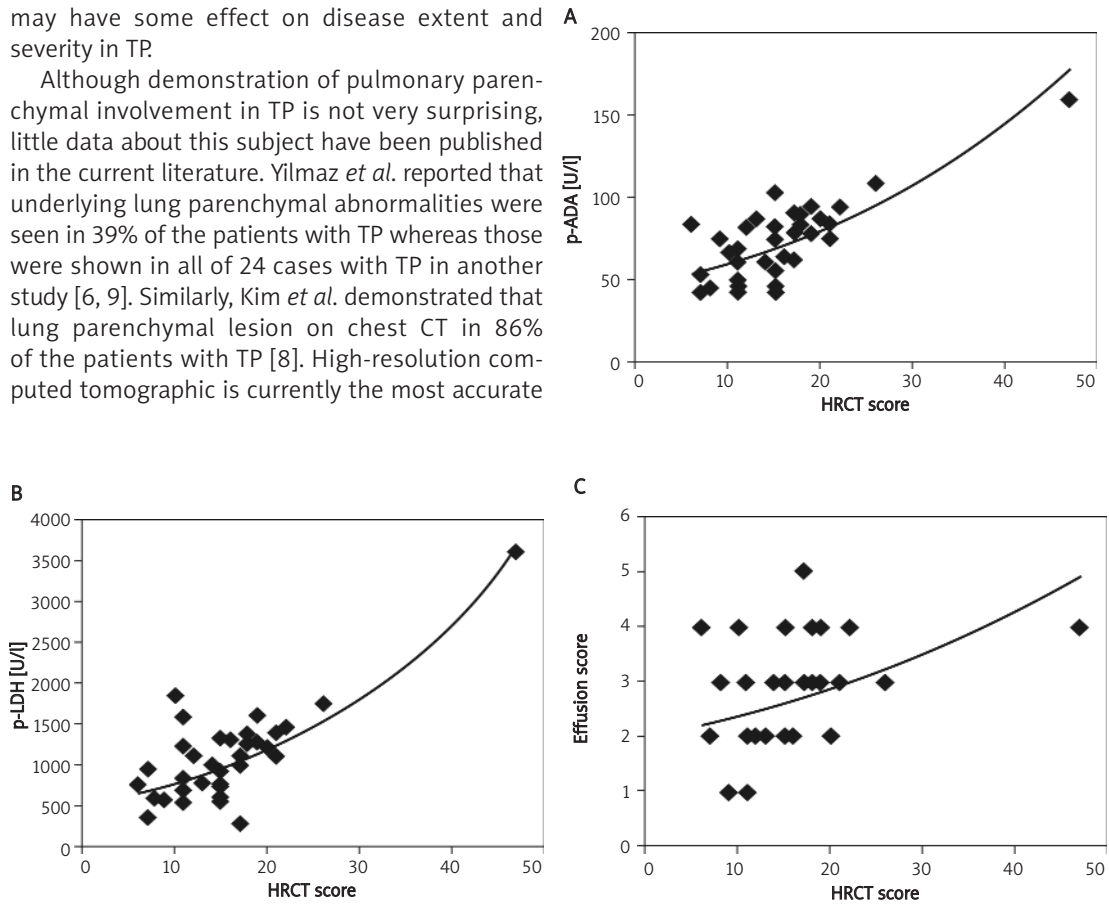


Figure 1. Correlations between HRCT scores and p-ADA (A), p-LDH (B) and effusion score (C)
p-ADA – pleural fluid adenosine deaminase, p-LDH – pleural fluid lactate dehydrogenase

Table II. Comparison of the patients according to mycobacterial culture results in sputum and pleural fluid samples

Parameter	Sputum culture			PF culture		
	positive (n = 6)	negative (n = 28)	p value	positive (n = 5)	negative (n = 29)	p value
HRCT score	25.5 ±10.9	13.4 ±4.0	< 0.001	24.4 ±13.8	14.0 ±4.4	0.038
Effusion score	3.5 ±0.5	2.7 ±0.9	0.042	2.8 ±1.1	2.8 ±0.9	NS
ESR [mm/h]	49.7 ±18.4	43.6 ±22.5	NS	54.8 ±10.1	42.9 ±22.8	NS
p-LDH [U/l]	1790.7 ±899.4	955.7 ±383.2	0.002	1703.6 ±1126.1	999.5 ±390.4	NS
p-protein [g/dl]	5.23 ±0.37	5.08 ±0.47	NS	5.10 ±0.48	5.11 ±0.46	NS
p-albumin [g/dl]	2.98 ±0.31	3.09 ±0.35	NS	2.96 ±0.34	3.09 ±0.34	NS
p-ADA [U/l]	101.8 ±29.8	67.8 ±17.6	0.002	94.6 ±42.2	70.2 ±17.8	NS
s-LDH [U/l]	450.3 ±111.7	407.1 ±69.4	NS	465.2 ±82.9	406.1 ±75.4	NS
s-protein [g/dl]	7.08 ±0.53	6.73 ±0.72	NS	6.98 ±0.60	6.76 ±0.71	NS
s-albumin [g/dl]	3.82 ±0.37	4.24 ±0.5	0.047	3.84 ±0.42	4.22 ±0.50	NS
s-ADA [U/l]	27.3 ±5.65	28.5 ±9.4	NS	29.6 ±5.2	28.1 ±9.3	NS
Sputum culture positivity	–	–	–	3 (60%) [1-5]*	3 (10.3%) [1-8]*	0.029
PF culture positivity	3 (50%) [1-5]*	2 (7.4%) [0-7]*	0.029	–	–	–

PF – pleural fluid, NS – not significant

* In parenthesis (percentage) and in brackets (95% confidence intervals of the cases)

non-invasive diagnostic tool for evaluation of lung parenchyma and it reveals many more lesions associated with active disease than chest X-ray does [12]. High-resolution computed tomographic can visualize cavities in hidden areas such as paramediastinal and retrocardiac areas, centrilobular nodules etc. However, all of the lung parenchymal lesions seen on HRCT scans in patients with TP may not necessarily indicate pulmonary TB. It is possible that pleural effusion, itself, might lead to atelectasis and parenchymal bands and consequently contribute to the HRCT score and this fact constitutes a limitation for our study.

The yield of sputum culture for *M.tb.* was 18% in our cases. The presence of *M.tb.* in the respiratory specimen has been previously reported [7, 8, 14, 15]; however data about this issue are controversial mainly due to differences in obtaining respiratory specimens. Conde *et al.* reported that yield of induced sputum culture for TB diagnosis was 55% [7]. In the other studies, this rate was reported as 30% in sputum or gastric lavage, 33% in sputum, gastric and bronchial lavage specimen and 33% in sputum and bronchial washings [8, 14, 15]. However, in an olden study, Arrington *et al.* reported that none of 25 patients with TP had a positive sputum or gastric lavage culture [16].

To our knowledge, as a first time in the literature, current study showed that HRCT scores of parenchymal changes correlated significantly with p-ADA and p-LDH. These enzymes are expressed much more in pleural fluid than serum in TP probably due to compartmentalization of the inflammatory cells, cytokines and enzymes and they are widely accepted as a degree of inflammation in TP [17-22]. High-resolution computed tomographic score also correlated with s-LDH, s-ADA, ESR and effusion score. However, we found no significant correlation between HRCT score and p-protein, p-albumin which may reflect degree of inflammation in pleural fluid. On the other hand, effusion score on chest X-ray, however, did not correlate with any of the abovementioned parameters. It has been showed that s-ADA levels may reflect extent of disease in TB and p-LDH and p-ADA can increase in correlation with degree of inflammation in TP [18-20, 22]. The positive and strong correlation of HRCT score with p-ADA and p-LDH made us suggest that degree of inflammation in TP might be related to pulmonary parenchymal changes, at least partially, but not to the size of the pleural effusion. Moreover, there is a significant correlation between HRCT score and effusion score suggesting that amount of fluid accumulated in the pleural space might be altered, in part, by pulmonary parenchymal involvement in TP. However, the reverse may be true, since larger pleural effusion might lead to higher HRCT score. On the other hand, one might

suggest that the case with the highest HRCT score as seen on Figure 1 is an outlier and by excluding that outlier case correlations might change. By omitting the outlier case of which HRCT score was 47, the correlation coefficients of HRCT score with p-ADA, p-LDH and effusion score (r_s values are 0.599, 0.506 and 0.376 respectively) were decreased but they are still statistically significant (p values are < 0.0001 , 0.003 and 0.031 respectively).

We have also found that *M.tb.* culture positivity in sputum specimen resulted in higher HRCT score, p-LDH, p-ADA and effusion score in patients with TP. The higher HRCT score the more culture positivity in sputum specimen is an expected finding and radiological extent of TB might correlate with various biochemical parameters [18, 19, 23]. However higher p-LDH, p-ADA levels and effusion score in TP patients with positive sputum culture for *M.tb.*, may indicate that *M.tb.* bacillus load in lung parenchyma might affect, at least in part, the pleural inflammation and size of the pleural effusion in TP. Higher pleural fluid *M.tb.* culture positivity among patients with a positive sputum culture supports this suggestion. Another interesting finding of our study is higher HRCT score among TP patients with a positive pleural fluid *M.tb.* culture. A possible explanation of this observation might be that extended pulmonary parenchymal involvement increases bacillus load in pleural space.

According to the current hypothesis, TP effusion develops from delayed hypersensitivity reaction to mycobacteria in the pleural space following rupture of a subpleural caseous focus [24] and it may cause various complications including fibrothorax, empyeme, and progression to pulmonary TB. Rapid disappearance of pleural fluid in use of corticosteroids supports this hypothesis [25]. Since effusion score and the levels of pleural inflammatory markers (p-LDH, p-ADA) are correlated with pulmonary parenchymal involvement and bacillus load as demonstrated in the current study, we suggest that bacillus load in underlying lung parenchyma might affect degree of delayed hypersensitivity.

According to the "WHO Report 2006, Global TB Control", extrapulmonary TB is defined as "a patient with tuberculosis of organs other than the lungs (e.g. pleura, lymph nodes, abdomen, genitourinary tract, skin, joints and bones, meninges) and a patient in whom both pulmonary and extrapulmonary tuberculosis has been diagnosed should be classified as a pulmonary case". In view of the results of our study and previous studies indicating that TP might have parenchymal lung changes consistent with TB and a positive *M.tb.* culture results in a considerable portion (as much as 86 and 55% respectively) [7, 8] of the patients with TP, we suggest that it should be reconsidered

whether TP is absolutely an extrapulmonary disease and it has a potential risk of contagiousness in some degree or not. However, this suggestion needs to be substantiated in further clinical and molecular epidemiological studies mainly due to major limitation of our study which is a relative small number of the study population.

We have concluded that *M.tb.* culture positivity in respiratory specimens and pulmonary parenchymal changes on HRCT may exist in TP and these findings affect pleural inflammation and size of the pleural effusion. As a result, it is more reasonable to suggest that TP might be a different manifestation of pulmonary TB or, at least, there is a relation between pulmonary parenchymal changes and pleural inflammation in TP. This fact should be born in mind in diagnosis and management of TP. Further clinical and epidemiological studies are to needed to make definite conclusions.

References

- Mathew J, Raj M, Dutta TK, Badhe BA, Sahoo R, Venkatesan M. Extra-pulmonary tuberculosis presenting as obstructive jaundice. *Arch Med Sci* 2007; 3: 73-5.
- Golden MP, Vikram HR. Extrapulmonary tuberculosis: an overview. *Am Fam Physician* 2005; 72: 1761-8.
- Tozkoparan E, Deniz O, Cakir E, et al. The diagnostic values of serum, pleural fluid and urine neopterin measurements in tuberculous pleurisy. *Int J Tuberc Lung Dis* 2005; 9: 1040-5.
- Gopi A, Madhavan SM, Sharma SK, Sahn SA. Diagnosis and treatment of tuberculous pleural effusion in 2006. *Chest* 2007; 131: 880-9.
- Krajewski W, Kasielski M, Król M, Białasiewicz P, Makówka A, Nowak D. The Abbott LCx-MTB assay is more sensitive than culture for detection of Mycobacterium tuberculosis in respiratory specimens. *Arch Med Sci* 2005; 1: 80-8.
- Hulnick DH, Naidich DP, McCauley DL. Pleural tuberculosis evaluated by computed tomography. *Radiology* 1983; 149: 759-76.
- Conde MB, Loivos AC, Rezende VM, et al. Yield of sputum induction in the diagnosis of pleural tuberculosis. *Am J Respir Crit Care Med* 2003; 167: 723-5.
- Kim HJ, Lee HJ, Kwon SY, et al. The prevalence of pulmonary parenchymal tuberculosis in patients with tuberculous pleuritis. *Chest* 2006; 129: 1253-8.
- Yilmaz MU, Kumcuoglu Z, Utkanaer G, Yalniz O, Erkmen G. Computed tomography findings of tuberculous pleurisy. *Int J Tuberc Lung Dis* 1998; 2: 164-7.
- Giusti G. Adenosine deaminase. In: Bergmyer H (ed.) *Methods of Enzymatic Analysis*. New York: Academic Press 1974; 1092-9.
- Casarini M, Ameglio F, Alemanno L, et al. Cytokine levels correlate with a radiological score in active pulmonary tuberculosis. *Am J Respir Crit Care Med* 1999; 159: 143-8.
- Tozkoparan E, Deniz O, Ciftci F, et al. The roles of HRCT and clinical parameters in assessing activity of suspected smear negative pulmonary tuberculosis. *Arch Med Res* 2005; 36: 166-70.
- Han DH, Song JW, Chung HS, Lee JH. Resolution of residual pleural disease according to time course in tuberculous pleurisy during and after the termination of anti-tuberculosis medication. *Chest* 2005; 128: 3240-5.
- Levine H, Metzger W, Lacera D, Kay L. Diagnosis of tuberculous pleurisy by culture of pleural biopsy specimen. *Arch Intern Med* 1970; 126: 269-71.
- Berger HW, Mejia E. Tuberculous pleurisy. *Chest* 1973; 63: 88-92.
- Arrington CW, Hawkins JA, Richert JH. Management of undiagnosed pleural effusions in positive tuberculin reactors. *Am Rev Respir Dis* 1966; 93: 587-93.
- Light RW. *Pleural diseases*. Philadelphia: Lea & Febiger 1983; 33-60.
- Lakshmi V, Rao RR, Joshi N, Rao PN. Serum adenosine deaminase activity in bacillary and paucibacillary pulmonary tuberculosis. *Indian J Pathol Microbiol* 1992; 35: 48-52.
- Collazos J, Espana P, Mayo J, Martinez E, Izquierdo F. Sequential evaluation of serum adenosine deaminase in patients treated for tuberculosis. *Chest* 1998; 114: 432-5.
- Porcel JM, Vives M. Etiology and pleural fluid characteristics of large and massive effusions. *Chest* 2003; 124: 978-83.
- Ernam E, Atalay F, Hasanoglu HC, Kaplan O. Role of biochemical tests in the diagnosis of exudative pleural effusions. *Clin Biochem* 2005; 38: 19-23.
- Pereira R, Medeiros YS, Fröde TS. Antiinflammatory effects of tacrolimus in a mouse model of pleurisy. *Transplant Immunology* 2006; 16: 105-11.
- Deniz O, Gumus S, Yaman H, et al. Serum total cholesterol, HDL-C and LDL-C concentrations significantly correlate with the radiological extent of disease and the degree of smear positivity in patients with pulmonary tuberculosis. *Clin Biochem* 2007; 40: 162-6.
- Chapman S, Davies RJ. The management of pleural space infections. *Respirology* 2004; 9: 4-11.
- Lee CH, Wang WJ, Lan RS, Tsai YH, Chiang YC. Corticosteroids in the treatment of tuberculous pleurisy: a double-blind placebo controlled randomized study. *Chest* 1988; 94: 1256-9.