

Risk of cerebral edema in children with diabetic ketoacidosis in the course of type 1 diabetes

Ryzyko wystąpienia obrzęku mózgu u dzieci z kwasicą ketonową w przebiegu cukrzycy typu 1

Aleksandra Pyziak, Wojciech Młynarski, Agnieszka Zmysłowska

Department of Paediatrics, Oncology, Hematology and Diabetology, Medical University of Lodz

Abstract

Diabetic ketoacidosis (DKA) is the most common acute complication of type 1 diabetes mellitus (T1DM) in children. Among all acute complications of T1DM, DKA is a complication with the greatest risk of cerebral edema. The aim of this article was to present current research on the assessment of the risk of cerebral edema in patients with diabetic ketoacidosis in the course of T1DM. The development of DKA in T1DM is associated with rapid changes in osmolality and the reduction of the brain tissue perfusion and decreased diffusion coefficient due to the dominance of the extracellular fluid or the impact of increased amounts of ketones on the endothelium. The assessment of the patient's neurological status is the primary measure aimed at early detection of cerebral edema in patients with DKA. As well, neuroimaging studies including CT and MRI are helpful in detecting brain edema but sometimes they can be too invasive and do not clearly correlate with the patient's clinical state. The assessment of dynamic changes in interleukin-1 and interleukin-8 concentrations in diabetic ketoacidosis at diagnosis and during the treatment of patients can also help to evaluate the risk of neurological complications and find the way to prevent them. Even a very careful observation of the patient with T1DM and ketoacidosis and an appropriate diagnosis and therapy do not allow for the exclusion of brain edema. These facts lead to the search for new biomarkers that allow for early assessment of the risk of cerebral edema.

Key words

type 1 diabetes, diabetes ketoacidosis, cerebral edema, diabetes complications

Streszczenie

Kwasica ketonowa (DKA) jest najczęstszym ostrym powikłaniem cukrzycy typu 1 (T1DM) u dzieci. Spośród wszystkich ostrych powikłań cukrzycy typu 1 kwasica ketonowa związana jest z największym ryzykiem wystąpienia obrzęku mózgu. Celem pracy było przedstawienie stanu wiedzy dotyczącego oceny ryzyka wystąpienia obrzęku mózgu u pacjentów z kwasicą ketonową w przebiegu cukrzycy typu 1. Szybkie zmiany osmolarności, zmniejszenie perfuzji tkanki mózgowej oraz zmniejszenie współczynnika dyfuzji z powodu dominacji płynu pozakomórkowego lub wpływu zwiększonej ilości ciał ketonowych na śródbłonek prowadzą do rozwoju DKA. Ocena stanu neurologicznego pacjenta jest podstawowym działaniem mającym na celu wczesne wykrycie obrzęku mózgu u pacjentów z kwasicą ketonową. Badania obrazowe: CT i NMR wykorzystywane w diagnostyce obrzęku mózgu nie zawsze korelują ze stanem klinicznym pacjenta, będąc równocześnie badaniami inwazyjnymi. Ocena zmian stężenia interleukiny-1 i stężenia interleukiny-8 wydaje się obiecującym sposobem oceny ryzyka wystąpienia powikłań neurologicznych, a także zapobiegania im. Uważna obserwacja pacjenta z kwasicą ketonową w przebiegu cukrzycy typu 1 oraz zastosowanie właściwego leczenia nie pozwalają wykluczyć obrzęku mózgu, co skłania do poszukiwania nowych biomarkerów pozwalających na dokładniejszą ocenę ryzyka wystąpienia obrzęku mózgu.

Słowa kluczowe

cukrzyca typu 1, kwasica ketonowa, obrzęk mózgu, powikłania cukrzycy

At the onset of type 1 diabetes mellitus (T1DM) about 10 up to 70% of the patients present diabetes ketoacidosis (DKA) [1]. Due to the fact that not all patients present the complication at the time of diagnosis, there is still the question of the triggers of DKA. While searching for the answer, the delay in diagnosis and treatment can be taken into account. Further, DKA occurs more often in more aggressive forms of the disease. Among the biochemical criteria for the diagnosis of this complication proposed by the ISPAD Guidelines 2014, the following parameters are mentioned: hyperglycemia (blood glucose >11 mmol/L), venous pH <7.3 or bicarbonate <15 mmol/L, ketonemia and ketonuria [2]. The clinical symptoms of ketoacidosis are dehydration, tachycardia, tachypnea, deep, sighing breath with a characteristic smell of acetone, nausea, vomiting and abdominal pain as well as the disturbance of consciousness. These symptoms may initially be mistaken for the infection of the respiratory or gastrointestinal tract [2].

The occurrence of DKA is a consequence of the significant insulin deficiency and is also associated with the increased level of counterregulatory hormones such as: catecholamine, glucagon, cortisol and the growth hormone. Insulin deficiency causes reduction in the glucose consumption primarily by muscle and adipose tissue. The production of glucose by gluconeogenesis and glycogenolysis also increases. This mechanism of imbalance between the levels of insulin and counterregulatory hormones leads to hyperglycemia and hyperosmolarity. Both processes are the source of osmotic diuresis and dehydration. This variability can also intensify ketogenesis and lipolysis. The consequence of the above-mentioned processes is strengthened dehydration, ketonemia and metabolic acidosis. Insulin resistance is also induced by the production of stress hormone during this vicious circle [2].

Younger children with lower body mass index and undergoing acute infection have been found to present DKA more frequently at the diagnosis of T1DM. The lack of health insurance and parents' educational state are also important [12]. The prevalence of DKA decreases with the age of children, ranging from 36% below the age of 5 to 16% over the age of 14 at diagnosis [3]. DKA is considered to be associated with the poor glycemic control in long term observations, hence with the lower incidence of partial clinical remission of T1DM [4].

In children and adolescents with previously identified T1DM, the frequency of DKA is about 1-10% per year [5]. Patients with established T1DM have most frequently demonstrated complications because of omitting insulin doses or due to the presence of infection [6]. Insulin deficiency can be observed quite often in the group of patients with psychiatric disorders, especially related to eating disorders and/or in peripubertal and adolescent girls. It is claimed that noncompliance was the reason for over 40% of DKA presentations [7]. Besides, missing out the insulin dose is generally related to the technical problems in insulin pumps [8]. DKA is also frequently noticed during an infection and acute medical states. Gastroenteritis, especially with vomiting and inability to maintain hydration can enhance the course of action leading to the demonstration of DKA [2]. It should also be borne in mind that some medicines

and exercises may promote DKA occurrence [9]. The previous DKA incident tends to more frequent occurrence of the further cases. Particularly, the poor metabolic control can predispose to this complication. It is noteworthy that an uncertain family situation or the distance to the reference center can have the influence [2]. Recently, some researchers also pay attention to the deficiency of thiamine and vitamin D in children with diabetic ketoacidosis in T1DM [10,11]. The authors suggest a possible effect of thiamine deficiency on the occurrence of cerebral complications in the course of DKA [11].

DKA complications are the most common cause of death in children with T1DM [12]. Hypoglycemia and hypokalemia belong to the most frequent complications of DKA. Other complications include hypocalcemia, sepsis, rhabdomyolysis, pulmonary edema, and acute renal failure. Among the complications related to functioning of the nervous system, cerebral edema, intracranial hemorrhage or cerebral infraction should be mentioned [2]. Even cerebral venous thrombosis can be observed in patients with DKA [2,12]. Nevertheless, it is suggested that only 10% of intracerebral crises are the result of conditions other than cerebral edema [13].

The aim of this article was to present current research on the assessment of the risk of cerebral edema in patients with diabetic ketoacidosis in the course of T1DM.

Symptomatic cerebral edema (CE) is stated in 0.7-1% of patients with DKA [14-16]. However, asymptomatic CE occurs probably more frequently [12,17]. CE in DKA is associated with mortality rate of about 40-90% and is considered to be the most common cause of death due to T1DM [18,19]. Up to one-third of affected patients survive with neurologic deficits and comorbidities [16,19-21]. Edge et al. have suggested that 35% of the patients after CE have severe neurological disabilities [22]. Even without the evident manifestation of cerebral edema, cognitive functions, especially memory, deteriorate during at least one episode of DKA [18]. Cerebral edema usually appears within the first 12 hours after the treatment has been started. In some cases it can be observed before or after 24 hours from the beginning of treatment [2,19]. Symptoms associated with suspected increasing intracranial pressure are the following: increasing headache, pupil asymmetry, nausea and vomiting, bradycardia, disturbances of consciousness and papilledema in the bottom of the eye (Table I) [18]. Neurological examination of the patient using diagnostic criteria based on bedside evaluation is essential for the diagnosis of cerebral edema in patients with diabetic ketoacidosis [2]. However, even a very careful observation of the patient with T1DM and DKA including monitoring of vital signs, maintaining fluid balance, repeated neurological examinations as well as an appropriate diagnosis and therapy do not allow clinicians to exclude brain edema. Furthermore, early treatment of CE is decisive for further occurrence of complications [23].

There are several hypotheses concerning the development of cerebral edema in DKA. The accumulation of water in the intracellular or extracellular spaces of the brain may occur through the cellular or vasogenic mechanisms. In the cellular mechanism, the incident of CE is associated with the rapid

Table I. Warning signs of cerebral edema

Tabela I. Objawy obrzęku mózgu

- Headache
- Bradycardia
- Elevated blood pressure
- Decreased oxygen saturation
- Anxiety
- Irritability
- Somnolence
- Incontinence
- Cranial nerve palsies
- Papilledema

changes in osmolarity occurring during intravenous infusion which cause sodium and water retention in the cells and an escape of water and plasma components into the tissue surrounding the brain [12,13].

Recent studies indicate that brain ischemia and vasogenic mechanism are more likely to cause brain edema in the course of diabetic ketoacidosis [12,16,19,24]. Children's brains are reported to have higher fuel and oxygen requirements than those of adults [23]. The considerable dehydration and hypocapnia related to acidosis and hyperventilation are reflected in vasoconstriction, causing ischemia and hypoxia. Hypoperfusion leads to cytotoxic edema- swelling and death of cells [12,25]. This process takes place through the breakdown of the blood brain barrier (BBB), leading to capillary leakage, which is reflected in vasogenic edema [12]. The impaired BBB could be a result of increased amounts of ketones that affect the endothelium and inflammatory response [16]. Increased vascular permeability is associated with the production of vasoactive peptides by excited brain endothelial cells. This process is stimulated by beta-hydroxybutyrate (OHB) and acetoacetate (AcAc), whose concentrations increase during ketoacidosis. Increased permeability can be also connected with the extended expression of intercellular adhesion molecule- 1 (ICAM-1) [24,26]. Increased activation of the Na-K-Cl cotransporter in cerebral capillary endothelial cells (CCEC) suggests the involvement of permeability in the CE [26]. Additionally, the occurrence of cerebral edema may be related to changes in perfusion during rehydration of the previous brain tissue ischemia and hyperglycemia and ketosis may make the brain more vulnerable to injury when hypocapnia occurs in children with DKA [24,27,28].

The presence of inflammation, increase in cytokines, activated lymphocytes, neutrophils, concentration of C-reactive protein, heat shock proteins and complement can also influence the development of cerebral and pulmonary edema in children with diabetic ketoacidosis at the diagnosis of T1DM [29,30]. Some researchers suggest that changes in the concentrations of pro-inflammatory (IL-1, IL-6, IL-8) and anti-inflammatory (IL-10) cytokines can affect the CE development. Changes in cytokine levels are noticeable both at the onset and during the treatment of DKA, depending on the severity

and also duration of diabetes [31]. For example, initially levels of IL-6 increased moderately and decreased over the 12 to 24 hours and TNF- levels were initially elevated and decreased over the subsequent 12 to 24 hours [18]. It is noteworthy that increased IL-6 and TNF- levels are observed in patients without DKA at the diagnosis of T1DM [30]. Their effects on endothelial inflammation and the occurrence of acute complications are also emphasized. In brain capillaries, the cytokine interleukin-6 (IL-6) is supposed to trigger the production of metalloproteinase inhibitors, such as alpha 2-macroglobulin, by perivascular astrocytes resulting in BBB failure and perivascular edema. Elevated CXCL1/CXCL8 mediates leukocyte endothelial adhesion, potentially contributing to DKA-associated intracranial vascular complications [29,30]. Leukocytes adhering to the endothelium produce reactive oxygen species (ROS), proteases, cationic proteins, and other substances that injure microvessels also affecting permeability of BBB [18]. Besides, increased leukocytosis present DKA course without an obvious infection reinforces the truth of anti-inflammatory action of insulin phenomenon [32]. Karavanaki et al. suggested that the prolonged elevation of hs-CRP levels in children with severe DKA could serve as a marker for the possible development of severe DKA complications, such as brain and pulmonary edema [33]. Moreover, during ketoacidosis, the increase in hormone levels, such as cortisol and the growth hormone is also observed, which can be related to tissue inflammatory response and reaction of the human body to changes in plasma glucose [30].

In autopsy, the relationship between inflammatory response and fatal CE in DKA was found by Hofman et al. They indicated an expression of IL-1 in neuroinflammatory response, the receptor for advanced glycation end products (RAGE) and the membrane attack complex C5b-9 on numerous cells and the microvasculature. They also observed intense expression of these proinflammatory mediators on the choroid plexus [26]. In other fatal DKA cases, Hoffman et al. presented neuronal deficits associated with a decreased presence of insulin and IGF-1 receptors and accumulation of nitrotyrosin in neurons of affected areas and the choroid plexus [34]. Cases of increased expression of 8OHG, HNE, HO-1, and Cp connected with oxidative stress in vulnerable brain regions were also described [35].

The role of genetic factors in the pathophysiology of CE in DKA is not clear [18]. A group of patients with T1DM require an insightful observation, or earlier, a more aggressive treatment because of their genetic profile. One example is the angiotensin converting enzyme (ACE) gene polymorphism affecting cerebral blood flows and indirect association between missense mutations in the CACNA1A calcium channel subunit gene and delayed cerebral edema [36].

Younger children are suggested to be more strongly predisposed to CE than the adolescents as well as the patients with newly diagnosed T1DM and long duration of symptoms [2,19,20]. Newly diagnosed diabetes was associated with about three times more risk of cerebral edema compared previously diagnosed diabetes [22]. Most of the cases of cerebral

Table II. Factors predisposing to cerebral edema possible to identify at diagnosis

Tabela II. Czynniki predysponujące do obrzęku mózgu ułatwiające postawienie rozpoznania

- younger patients
- newly diagnosed diabetes
- long duration of symptoms
- higher serum urea nitrogen and creatinine concentration
- more severe hypocapnia
- lower initial bicarbonate
- higher glucose

edema occur in severe and moderate type of ketoacidosis. But, according to some authors, even a mild ketoacidosis puts the patient at risk of cerebral edema [22]. It is worth noting that also higher serum urea nitrogen and creatinine concentrations, more severe hypocapnia, lower initial bicarbonate and higher glucose at presentation are connected with the higher cerebral edema risk compared to the control group (Table II) [12,19,21]. However, these markers are specific only for the current ketoacidosis, but not sufficient for assessing a risk of cerebral edema. Interestingly, there are no differences between patients with malnutrition and those normally nourished in terms of the frequency of diagnosis of brain edema [37].

Changes in blood osmolarity and sodium, glucose, urea concentrations during treatment have also been highlighted as the potential risk factors for CE [12,19,38]. Sodium and its variability by changes in blood glucose is suggested as the most important [38]. Another risk factor connected with rapid changes in electrolyte concentrations is the administration of insulin in the first hour of fluid treatment [17,19,20]. Greater volumes of fluid given during first four hours of treatment also predispose to CE and there are no significant associations between the amount of potassium administered and the risk of the development of CE. Egde et al. suggested that the dose of insulin administered over the first 2 hours was also significantly associated with the risk of CE (Fig. 1) [20]. During the treatment of DKA,

bicarbonate could be also an important risk factor because of the decreased cerebral O₂ availability; this cerebral hypoxia contributes to the brain dysfunction [19]. Indications for administration of bicarbonate in DKA treatment is limited: a solution of 8.4 % sodium bicarbonate (NaHCO₃) is administered in the case of very severe acidosis (pH <7.0) or at pH <7.1, if the patient is in shock, they have arrhythmia and cardiac failure [9]. Furthermore, some authors have suggested a bicarbonate infusion to be the only significant treatment-related CE risk factor [19]. In the case of the suspected CE, it is important to give immediately an infusion of hypertonic mannitol at a dose as high as 1 g/kg body weight and to restrict fluids. Among other effective therapeutic tools, intubation protecting the airway and hypertonic saline infusions are mentioned. Measures used in intracranial hypertension have no proven benefit in the CE treatment [23]. Nevertheless, symptomatic CE was observed in a few cases before the beginning of the treatment, which confirms that the treatment cannot be the cause of the CE and can only aggravate the process [12,17]. Subclinical symptoms of cerebral edema were also imaging prior to intravenous fluids and insulin therapy [16].

Even the evaluation of cerebral edema based on the CNS imaging studies such as CT (computed tomography) or MRI (magnetic resonance imaging), which are immediately performed after the onset of neurological symptoms seems to be unsatisfactory considering invasiveness and limited availability of the studies, their high cost and the possibility to visualize already present lesions in the brain. In addition, the radiological features of cerebral edema without clinical symptoms are present in 50% of children treated for ketoacidosis [17,39]. On the other hand, Muir et al. noted that about 40% of patients with clinical CE symptoms had no abnormalities in CT. Another 40% had diffuse cerebral edema, and 30% had intracranial hemorrhage, either alone or in combination with cerebral edema [23,39]. It is possible that edema is rather a consequence than the cause of injury [12,23]. Among the changes observed by CT in patients with CE, an effacement of the sulci and basilar cisternal spaces, the compression and decreased size of the cerebral ventricles, and the reduction of the gray-white matter differentiation are mainly mentioned. The researchers also sug-

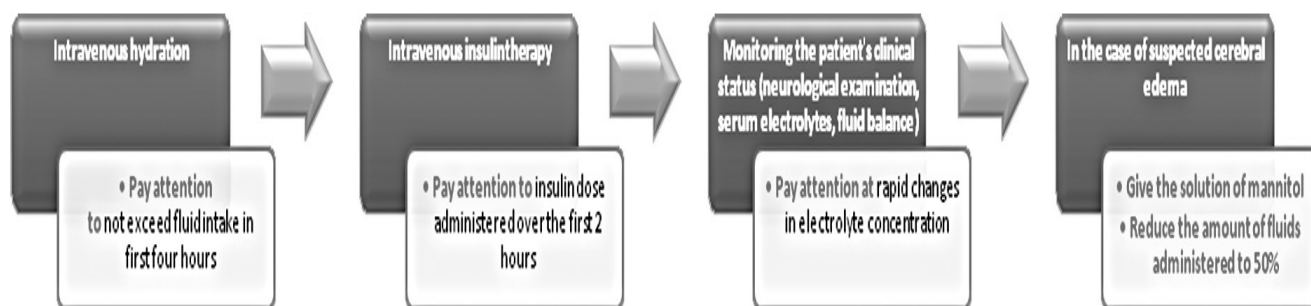


Fig. 1. Treatment of diabetic ketoacidosis
Ryc. 1. Postępowanie w kwasicy ketonowej

gested that in CT scans the lateral ventricles are significantly smaller during the DKA treatment than after recovery [17].

MRI performed in patients during DKA has shown the elevated apparent diffusion coefficient (ADC) and increased cerebral blood flow suggesting a vasogenic process [40,41]. Especially ADC values were elevated in the basal ganglia, thalamus, frontal white matter, and periaqueductal gray matter. These areas are considered to be the most susceptible to ischemic injury and as being the areas of a high ATP demand [39]. Glaser et al. have also demonstrated a positive correlation between ADC and the initial serum urea nitrogen [41]. The vasogenic mechanism can also be confirmed by observations of increased tissue water by T2 relaxometry [42]. During the MRI the hyperintensity areas of the brain which cause hypoglycemia are also visible [39]. Abnormal signal changes in the frontal region with suggested edema are observed on fluid attenuated inversion recovery (FLAIR) MR imaging. Increased taurine, myoinositol and glucose levels have also been seen in MR spectroscopy (MRS). These abnormalities varied in severity but did not correlate with any clinical or biochemical parameters [43]. MRS also shows the reduced N-acetylaspartate (NAA) level [44]. Diffusion-weighted Imaging Magnetic Reso-

nance (DWI MR) changes consistent with vasogenic edema have been shown in children during the treatment of DKA [41].

Moreover, the ultrasonography may serve as a probable early marker of the CE risk. Interesting studies concerning the assessment of the middle cerebral artery flow and cerebral autoregulation were tested using Doppler ultrasonography. It was noted that the impaired cerebral autoregulation was common during an early treatment of diabetic ketoacidosis [45]. Hansen et al. have also suggested that subtle changes in intracranial pressure may be detected with optic nerve sheath diameter (ONSD) ultrasonography in pediatric patients with DKA [46].

Doubtless, finding a clinically useful marker that allows, an easy and quick assessment of the risk of cerebral edema in children with DKA requires further exploration. The correct estimation of the symptoms and signs of DKA and an overall assessment of the patient's clinical status remain very important issues in the evaluation of the risk of cerebral edema. The noninvasive tests to assess the intracranial pressure and magnetic resonance imaging as well as those relating to changes in the concentration of inflammatory markers seem to be very promising.

References

1. Usher-Smith JA, Thompson MJ, Sharp SJ, Walter FM. *Factors associated with the presence of diabetic ketoacidosis at diagnosis of diabetes in children and young adults: a systematic review*. *BMJ*. 2011; 343: d4092-d4092.
2. Wolfsdorf JL et al. *ISPAD Clinical Practice Consensus Guidelines 2014. Diabetic ketoacidosis and hyperglycemic hyperosmolar state*. *Pediatr Diabetes*. 2014; 15 Suppl 2: 154-179.
3. Wolfsdorf J, Glaser N, Sperling MA. *Diabetic Ketoacidosis in Infants, Children, and Adolescents: A consensus statement from the American Diabetes Association*. *Diabetes Care*. 2006; 29: 1150-1159.
4. Bowden SA, Duck MM, Hoffman RP. *Young children (<5 yr) and adolescents (>12 yr) with type 1 diabetes mellitus have low rate of partial remission: diabetic ketoacidosis is an important risk factor*. *Pediatr Diabetes*. 2008; 9: 197-201.
5. Curtis JR, To T, Muirhead S, Cummings E, Daneman D. *Recent trends in hospitalization for diabetic ketoacidosis in Ontario children*. *Diabetes Care*. 2002; 25: 1591-1596.
6. Morris AD et al. *Adherence to insulin treatment, glycaemic control, and ketoacidosis in insulin-dependent diabetes mellitus. The DARTS/MEMO Collaboration. Diabetes Audit and Research in Tayside Scotland. Medicines Monitoring Unit*. *Lancet*. 1997; 350: 1505-10.
7. Rewers A et al. *Predictors of acute complications in children with type 1 diabetes*. *JAMA*. 2002; 287: 2511-2518.
8. Hanas R, Lindgren F, Lindblad BA. *2-yr national population study of pediatric ketoacidosis in Sweden: predisposing conditions and insulin pump use*. *Pediatr Diabetes*. 2009; 10: 33-7.
9. Ciecchanowska M, Starzyk J. *Kwasica ketonowa w przebiegu cukrzycy typu 1 u dzieci. Rozpoznanie i leczenie chorego w pierwszej dobie hospitalizacji*. *Endocrinology, Obes. Metab. Disord*. 2009; 5: 28-35.
10. Al-Zubeidi H, Leon-Chi L, Newfield RS. *Low vitamin D level in pediatric patients with new onset type 1 diabetes is common, especially if in ketoacidosis*. *Pediatr Diabetes*. 2015; doi:10.1111/pedi.12342.
11. Rosner EA, Strezlecki KD, Clark JA, Lieh-Lai M. *Low Thiamine Levels in Children With Type 1 Diabetes and Diabetic Ketoacidosis: A Pilot Study*. *Pediatr. Crit. Care Med*. 2015; 16(2):114-8.
12. Bialo SR, Agrawal S, Boney CM, Quintos JB. *Rare complications of pediatric diabetic ketoacidosis*. *World J. Diabetes*. 2015; 6: 167-174.
13. Rosenbloom AL. *Intracerebral crises during treatment of diabetic ketoacidosis*. *Diabetes Care*. 1990; 13, 22-33.
14. Kitabchi AE, Umpierrez GE, Murphy MB, Kreisberg RA. *Hyperglycemic Crises in Adult Patients With Diabetes: A consensus statement from the American Diabetes Association*. *Diabetes Care*. 2006; 29: 2739-2748.
15. Carlotti AP, Bohn, D, Halperin ML. *Importance of timing of risk factors for cerebral oedema during therapy for diabetic ketoacidosis*. *Arch. Dis. Child*. 2003; 88: 170-173.
16. Tasker RC, Acerini CL. *Cerebral edema in children with diabetic ketoacidosis: Vasogenic rather than cellular?* *Pediatr. Diabetes*. 2014; 15: 261-270.
17. Glaser NS, et al. *Frequency of sub-clinical cerebral edema in children with diabetic ketoacidosis*. *Pediatr. Diabetes*. 2006; 7: 75-80.
18. Jarvis JD, Flori HR. *Biomarkers and genetics of brain injury risk in diabetic ketoacidosis: A pilot study Sholeen*. *J Pediatr Intensive Care*. 2015; 3: 1-15.
19. Glaser N et al. *Risk factors for cerebral edema in children with diabetic ketoacidosis*. *N Engl J Med*. 2001; 344(4): 264-9.
20. Edge JA et al. *The UK case-control study of cerebral oedema complicating diabetic ketoacidosis in children*. *Diabetologia*. 2006; 49: 2002-2009.
21. Lawrence SE, Cummings EA, Gaboury I, Daneman D. *Population-based study of incidence and risk factors for cerebral edema in pediatric diabetic ketoacidosis*. *J. Pediatr*. 2005; 146: 688-692.
22. Edge JA, Hawkins MM, Winter DL, Dunger DB. *The risk and outcome of cerebral oedema developing during diabetic ketoacidosis*. *Arch. Dis. Child*. 2001; 85: 16-22.

23. Muir AB, Quisling RG, Yang MC, Rosenbloom AL. *Cerebral edema in childhood diabetic ketoacidosis: natural history, radiographic findings, and early identification*. Diabetes Care. 2004; 27, 1541-1546.
24. Glaser NS, et al. *Mechanism of cerebral edema in children with diabetic ketoacidosis*. J. Pediatr. 2004; 145: 164-171.
25. Levin DL. *Cerebral edema in diabetic ketoacidosis*. Pediatr. Crit. Care Med. 2008; 9: 320-329.
26. Hoffman WH, Stamatovic SM, Andjelkovic AV. *Inflammatory mediators and blood brain barrier disruption in fatal brain edema of diabetic ketoacidosis*. Brain Res. 2009; 1254: 138-148.
27. Vavilala MS et al. *Change in blood-brain barrier permeability during pediatric diabetic ketoacidosis treatment*. Pediatr Crit Care Med. 2010; 11: 332-338.
28. Sambasivarao SV. *Brain Cell Swelling During Hypocapnia Increases with Hyperglycemia or Ketosis*. Pediatr Diabetes. 2013; 18: 1199-1216.
29. Omatsu T et al. *CXCL1/CXCL8 (GRO α /IL-8) in human diabetic ketoacidosis plasma facilitates leukocyte recruitment to cerebrovascular endothelium in vitro*. Am. J. Physiol. Endocrinol. Metab. 2014; 306: E1077-84.
30. Karavanaki K et al. *Cytokine response to diabetic ketoacidosis (DKA) in children with type 1 diabetes (T1DM)*. Endocr. J. 2011; 58: 1045-1053.
31. Erbagci AB et al. *Mediators of inflammation in children with type I diabetes mellitus: cytokines in type I diabetic children*. Clin Biochem. 2001; 34: 645-650.
32. Dandona P, Aljada A, Mohanty P. *The anti-inflammatory and potential anti-atherogenic effect of insulin: a new paradigm*. Diabetologia. 2002; 45: 924-930.
33. Karavanaki K, et al. *Plasma high sensitivity C-reactive protein and its relationship with cytokine levels in children with newly diagnosed type 1 diabetes and ketoacidosis*. Clin Biochem. 2012; 45: 1383-1388.
34. Hoffman WH et al. *Insulin and IGF-1 receptors, nitrotyrosin and cerebral neuronal deficits in two young patients with diabetic ketoacidosis and fatal brain edema*. Brain Res. 2010; 1343: 168-177.
35. Hoffman WH et al. *Oxidative Damage is Present in the Fatal Brain Edema of Diabetic Ketoacidosis*. Brain Res. 2011; 1369: 194-202.
36. Jordan BD. *Genetic influences on outcome following traumatic brain injury*. Neurochem. Res. 2007; 32: 905-915.
37. Moulik NR et al. *Nutritional status and complications in children with diabetic ketoacidosis*. Pediatr. Crit. Care Med. 2012; 13: e227-33.
38. Durward A et al. *The temporal relationship between glucose-corrected serum sodium and neurological status in severe diabetic ketoacidosis*. Arch. Dis. Child. 2011; 96: 50-57.
39. Wootton-Gorges SL, Glaser NS. *Imaging of the brain in children with type I diabetes mellitus*. Pediatr. Radiol. 2007; 37: 863-9.
40. Glaser NS et al. *Subclinical cerebral edema in children with diabetic ketoacidosis randomized to 2 different rehydration protocols*. Pediatrics. 2013; 131: e73-80.
41. Glaser NS et al. *Correlation of clinical and biochemical findings with diabetic ketoacidosis-related cerebral edema in children using magnetic resonance diffusion-weighted imaging*. J. Pediatr. 2008; 153: 541-6.
42. Figueroa RE et al. *Study of subclinical cerebral edema in diabetic ketoacidosis by magnetic resonance imaging T2 relaxometry and apparent diffusion coefficient maps*. Endocr Res. 2005; 31: 345-355.
43. Cameron FJ et al. *Insights into the acute cerebral metabolic changes associated with childhood diabetes*. Diabet Med. 2005; 22: 648-653.
44. Cameron FJ et al. *Neurological consequences of diabetic ketoacidosis at initial presentation of type 1 diabetes in a prospective cohort study of children*. Diabetes Care. 2014; 37: 1554-1562.
45. Hoffman WH et al. *Transcranial Doppler ultrasound assessment of intracranial hemodynamics in children with diabetic ketoacidosis*. J. Clin. ultrasound JCU. 1995; 23: 517-523.
46. Hansen G et al. *Optic Nerve Sheath Diameter Ultrasonography in Pediatric Patients with Diabetic Ketoacidosis*. Can. J. Diabetes. 2015; doi:10.1016/j.jcjd.2015.07.007.