

# Quadricuspid aortic valve

Jagroop S. Saran, Marcin Wąsowicz

Toronto General Hospital, University Health Network, University of Toronto, Canada

Dear Editor,

Quadricuspid aortic valve (QAV) is an extremely rare congenital cardiac defect with an estimated incidence of 0.01–0.05% based on autopsy and echocardiography databases [1]. It is usually an isolated defect but can be associated with other congenital heart abnormalities including altered coronary artery anatomy and coronary ostium abnormalities, atrial or ventricular septal defects, patent ductus arteriosus, subaortic stenosis, pulmonary valve stenosis, mitral valve prolapse, and hypertrophic cardiomyopathy. It may also coexist with aortic dilatation of the aortic root and/or ascending aorta. The most common functional consequence is purely regurgitation although it may present as mixed stenosis/regurgitation.

Patients with isolated QAV are typically asymptomatic until the fifth or sixth decade of life [2]. Surgical intervention is indicated for severe aortic regurgitation or stenosis or a dysfunctional QAV associated with other

lesions, particular coronary artery or ostia abnormalities. It is also recommended for asymptomatic patients with decreased left ventricle (LV) systolic function (LV ejection fraction < 50%) or enlargement (LV end systolic diameter > 55 mm or LV end diastolic diameter > 75 mm) [3].

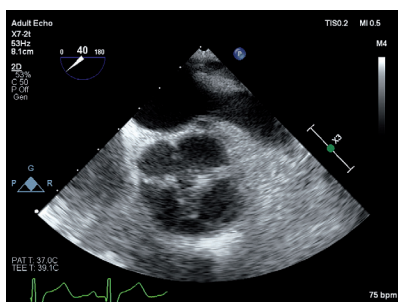
Transesophageal echocardiography can demonstrate aortic valve morphology including cusps, coaptation defects, aortic root and ascending aorta dimensions, and severity of regurgitation. The aortic valve, seen intraoperatively in the mid esophageal aortic valve short axis view, in diastole, reveals the four cusps (Figure 1). The QAV consists of three equal size cusps and one smaller supernumerary cusp located between the left and noncoronary cusps in the 10 o'clock position consistent with the type B classification proposed by Hurwitz and Roberts [3].

## ACKNOWLEDGEMENTS

1. Financial support and sponsorship: none.
2. Conflicts of interest: none.

## REFERENCES

1. Tsang MY, Abudiab MM, Ammash NM, et al. Quadricuspid aortic valve: characteristics, associated structural cardiovascular abnormalities, and clinical outcomes. *Circulation* 2016; 133: 312-319. doi: 10.1161/CIRCULATIONAHA.115.017743.
2. Brzezinski M, Mertz V, Clements FM, et al. Transesophageal echocardiography of the quadricuspid aortic valve. *Anesth Analg* 2006; 103: 1414-1415. doi: 10.1213/01.ane.0000243390.30837.5f.
3. Hurwitz LE, Roberts WC. Quadricuspid semilunar valve. *Am J Cardiol* 1973; 31: 623-626. doi: 10.1016/0002-9149(73)90332-9



**FIGURE 1.** Transesophageal echocardiogram of the aortic valve in short axis, in diastole, revealing four cusps

*Anaesthesiol Intensive Ther* 2019; 51, 5: 420–420

## CORRESPONDING AUTHOR:

Dr. Jagroop S. Saran, Toronto General Hospital, University Health Network, University of Toronto, Canada, e-mail: [jagroopsaranmd@gmail.com](mailto:jagroopsaranmd@gmail.com)