

# Erector spinae plane block for postoperative analgesia in thoracoscopic lobectomy in a paediatric patient

Juan Manuel Gomez-Menendez, Fabricio Andres Caballero-Lozada, Fabricio Barahona-Cabrera, Victor Urueta-Gaviria, Andrés Zorrilla-Vaca

*Department of Anaesthesiology, Universidad del Valle, Cali, Colombia*

Dear Editor,

Opioid-free management of pain in paediatric patients is considered a challenge for anaesthesiologists [1]. In recent years, ultrasound-guided peripheral blocks have gained popularity due to their safety and efficacy in providing pain relief and rapid recovery. Recently, the erector spinae plane (ESP) block has been used for postoperative analgesia for open heart surgery, oncological thoracic surgery, and abdominal laparoscopic procedures in paediatric populations [2–5]. Herein we report a case of a single-shot ESP block for postoperative analgesia in a paediatric patient undergoing thoracoscopic lobectomy.

A 13-month-old male patient with an intralobar sequestration in the right lung was scheduled for lobectomy via video-assisted thoracoscopy. Balanced anaesthesia was given as follows: after pre-oxygenation with 100% O<sub>2</sub> for 3 min, anaesthesia was induced with injection of propofol 6 mg *i.v.* plus fentanyl 20 µg, cisatracurium 1.4 mg, and maintenance with balanced anaesthesia with sevoflurane 1 minimum alveolar concentration and remifentanyl 1.5 µg min<sup>-1</sup> for intraoperative analgesia. There were no intraoperative complications. Following completion of the surgery, which lasted 2.5 hours, and with parental consent, the patient was placed in the lateral decubitus position and given standard analgesia of 1.5 g dipyrone and 0.1 mg hydromorphone as well as an ultrasound-guided single-shot ESP block using a 22 G, 60-mm needle that was directed toward the tip of the T4 transverse process (Figure 1A).

This was also followed by an injection of 5 mL of bupivacaine 0.25% (Figure 1B) by visualising the craniocaudal spread of the local anaesthetic and dissection of the fascia (Figure 1C). Haemodynamic parameters were stable and emergence from anaesthesia was uneventful.

Assessment of pain was done by using the Wong-Baker FACES scale [6]. Rescue analgesic was given if FACES scale score was ≥ 3 with methimazole plus paracetamol. During the postoperative period, only multimodal analgesia with methimazole plus paracetamol was given at 1, 24, and 48 hours postoperatively without the need of any rescue with opioids. FACES score at the time of rescue analgesic was 3.1 ± 0.4 and FACES score at 24 hours was 0.6 ± 1.1. The patient was discharged three days after surgery without any evidence of perioperative pain. We did not see evidence of any side effects such as postoperative sedation, nausea and vomiting, pruritus, or respiratory depression (RR < 10 or SpO<sub>2</sub> < 90%).

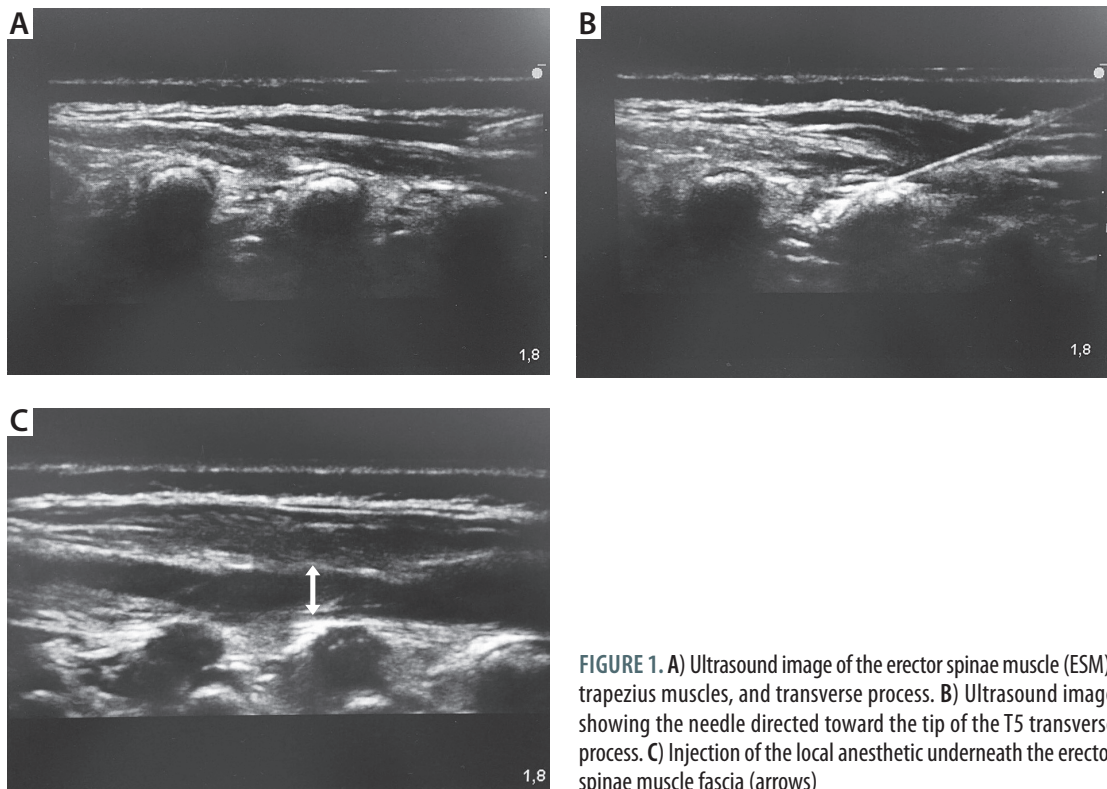
In this case, we have demonstrated that the ESP block is a safe and effective option to provide postoperative analgesia for a minimally invasive surgery of the lung. This novel technique has been used for both acute and chronic pain management. In studies with cadaveric models, it has been proven that the spread of local anaesthetic may provide an extensive sensory block between C7 and T8, allowing for excellent analgesia in numerous thoracic and abdominal surgeries.

A minor difference of the ESP block described in this case was the de-

Anaesthesiol Intensive Ther 2019; 51, 2: 166–167

## CORRESPONDING AUTHOR:

Andrés Zorrilla-Vaca, Department of Anaesthesiology, Universidad del Valle, Cali, Colombia, e-mail: [andres.zorrilla@correounivalle.edu.co](mailto:andres.zorrilla@correounivalle.edu.co)



**FIGURE 1.** A) Ultrasound image of the erector spinae muscle (ESM), trapezius muscles, and transverse process. B) Ultrasound image showing the needle directed toward the tip of the T5 transverse process. C) Injection of the local anesthetic underneath the erector spinae muscle fascia (arrows)

creased amount of local anaesthetic used, which lowered the risk of toxicity but yielded excellent analgesic results. The amount of local anaesthetic recommended for ESP block is still a matter of discussion; the dissection of the erector spinae fascia, as shown in Figure 1C, is not an accurate form to establish the dose required to ensure an acceptable block. However, a general recommendation is to inject in the fascial blocks  $0.25\%$  bupivacaine  $0.2\text{--}0.5\text{ mL kg}^{-1}$ . After compilation of all cases of ESP block in paediatric populations [2–5], we hypothesise numerous advantages compared with neuraxial analgesia, such as: 1) decreased risk of neurologic complications (e.g. spinal cord injury), 2) prolonged analgesia, 3) faster recovery with opioid-sparing properties, and 4) better opioid-induced side-effect profile.

To our knowledge, this is the first case report of an ESP block in a paediatric patient undergoing video-assisted thoracoscopy for lobectomy. We also provided a clear illustration in which readers can easily visualise the technique and anatomy after a successful ESP block. The opioid-sparing effect

of this technique seems to facilitate rapid postoperative recovery and early discharge. Further cases of ESP block in painful surgeries, such as the correction of the pectus excavatum deformity, are needed to better analyse its utility. Finally, we encourage the development of a randomised controlled trial to compare this technique with conventional epidural or paravertebral blocks to further draw conclusions on this topic.

#### ACKNOWLEDGEMENTS

1. Source of funding: none.
2. Conflict of interest: none.

#### REFERENCES

1. Forero M, Adhikary SD, Lopez H, Tsui C, Chin KJ. The erector spinae plane block a novel analgesic technique in thoracic neuropathic pain. *Reg Anesth Pain Med* 2016; 41: 621–627. doi: 10.1097/AAP.0000000000000451.
2. Muñoz F, Cubillos J, Bonilla AJ, Chin KJ. Erector spinae plane block for postoperative analgesia in pediatric oncological thoracic surgery. *Can J Anesth* 2017; 64: 880–882. doi: 10.1007/s12630-017-0894-0.
3. Hernandez MA, Palazzi L, Lapalma J, Forero M, Chin KJ. Erector spinae plane block for surgery of the posterior thoracic wall in a pediatric patient. *Reg Anesth Pain Med* 2018; 43: 217–219. doi: 10.1097/AAP.0000000000000716.
4. Ueshima H, Otake H. Clinical experiences of erector spinae plane block for children. *J Clin Anesth* 2018; 44: 41. doi: 10.1016/j.jclinane.2017.10.021.
5. Willard FH, Vleeming A, Schuenke MD, Danneels L, Schleip R. The thoracolumbar fascia: Anatomy, function and clinical considerations. *J Anat* 2012; 221: 507–536. doi: 10.1111/j.1469-7580.2012.01511.x.
6. Chambers CT, Giesbercht K, Craig KD, Bennett SM, Huntsman E. A comparison of faces scales for the measurement of paediatric Children's and parents' ratings. *Pain* 1999; 83: 25–35.