

Missing atrioventricular echogenic mass during paediatric HeartWare® implantation

Kemal Tolga Saracoglu¹, Ayten Saracoglu², Ayhan Cevik³, Ibrahim Haluk Kafali¹

¹Department of Anesthesiology and Intensive Care, Istanbul Bilim University Medical School, Turkey

²Department of Anesthesiology and Intensive Care, Istanbul Marmara University Medical School, Turkey

³Department of Pediatric Cardiology, Istanbul Bilim University Medical School, Turkey

To the Editor,

While awaiting for heart transplantation, left ventricular assist device implantation has become a well-established treatment for children with end-stage heart failure [1]. During the implantation, a left or right atrial mobile mass may be visualized by transesophageal echocardiography [2]. Even the differential diagnosis can be challenging, mostly consisting of a primary or metastatic cardiac tumour, vegetation or a thrombus [3]. However, determination of a new atrial mobile mass with irregular borders typically raises concern of a thrombus which carries the risks of systemic embolization [4].

A 5-year-old boy with a history of several surgeries, including the Senning procedure for correction of transposition of the great arteries, pulmonary artery banding, ventricular septal defect surgery, and tricuspid valve ring annuloplasty, presented with multiple organ dysfunction syndrome. During a *transthoracic echocardiography*, left ventricular *ejection fraction* was assessed at 10%. The patient underwent implantation of a HeartWare® continuous-flow left ventricular assist device. Transesophageal echocardiography demonstrated an echogenic mass formation in the right atrium (Fig. 1) and the left ventricle (Fig. 2). The echo probe was in place throughout the procedure and continuous images were acquired. After 15 minutes time, first the atrial and then the ventricular thrombus-like images just vanished in an instant, without observing any

changes or stages of resolution. The images were recorded following the implantation of an assist device. Immediately after the surgery, no thromboembolic complications were observed. A Doppler ultrasound examination of the blood circulation in the upper and lower extremities showed no thrombus formation. In conclusion, we have come across a highly unusual case of echogenic mass formation both in the right atrium and left ventricle that developed during implantation of an isolated permanent continuous-flow left ventricular assist device (HeartWare®). Although this could have been an artefact, acute systemic embolization may be a life-threatening condition and should be excluded in the early postoperative period.

ACKNOWLEDGEMENTS

1. Source of funding: none.
2. Conflict of interest: none.
3. Written informed parent consent was obtained for publication of this report.

References:

1. Kucukaksu SD, Demirozu ZT, Pektok E, et al. Emergency veno-arterial extracorporeal membrane oxygenation with Levitronix centrifugal pump for bridging to Heart Ware left ventricular assist device implantation. *Chirurgia*. 2014; 27: 305–307.
2. Apostolidou I, Sweeney MF, Missov E, et al. Acute left atrial thrombus after recombinant factor VIIa administration during left ventricular assist device implantation in a patient with heparin-induced thrombocytopenia. *Anesth Analg*. 2008; 106(2): 404–408, doi: [10.1213/ane.0b013e31815ed52](https://doi.org/10.1213/ane.0b013e31815ed52), indexed in Pubmed: [18227291](https://pubmed.ncbi.nlm.nih.gov/18227291/).
3. Mazzeffi M, Brown J, Bernstein W, et al. An Unusual Right Atrial Mass: A Misdiagnosis Identified by Intraoperative Transesophageal Echocardiography. *J Cardiothorac Vasc Anesth*. 2016; 30(1): 263–265, doi: [10.1053/j.jvca.2015.06.031](https://doi.org/10.1053/j.jvca.2015.06.031), indexed in Pubmed: [26442454](https://pubmed.ncbi.nlm.nih.gov/26442454/).
4. Maldonado Y, Troianos CA, Marks B, et al. Echo rounds: intraoperative transesophageal echocardiography of a left atrial mass after total artificial heart implantation. *Anesth Analg*. 2013; 117(3): 587–589, doi: [10.1213/ANE.0b013e31829f9ed2](https://doi.org/10.1213/ANE.0b013e31829f9ed2), indexed in Pubmed: [23868892](https://pubmed.ncbi.nlm.nih.gov/23868892/).

Adres do korespondencji:

Kemal Tolga Saracoglu, MD

Florence Nightingale Hospital, Abide-i Hurriyet Cad.

No: 164 Sisli Caglayan, Istanbul, Turkey

e-mail: saracoglu@gmail.com

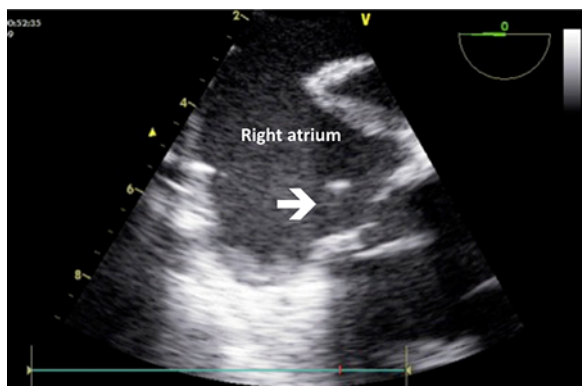


Figure 1. Echogenic thrombus formation in the right atrium

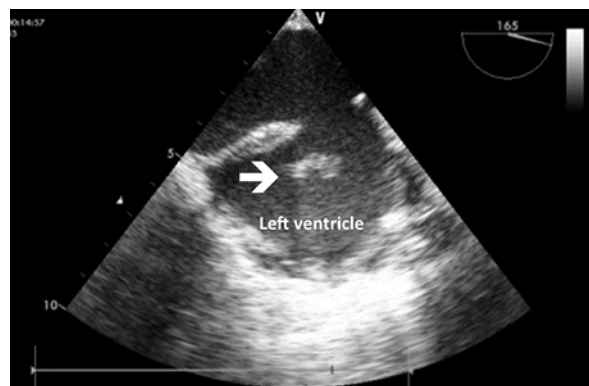

Figure 2. Echogenic thrombus formation in the left ventricle

Należy cytować wersję: Tolga Saracoglu K, Saracoglu A, Cevik A, Haluk Kafali I. Missing atrioventricular echogenic mass during paediatric HeartWare® implantation. *Anaesthesiol Intensive Ther* 2017, vol. 49, no 2, 174. doi: [10.5603/AIT.a2017.0018](https://doi.org/10.5603/AIT.a2017.0018).